

WARNING

Concerning Copyright Restrictions

The copyright law of the United States (Title 17, United States Code) governs the making of photocopies or other reproductions of copyrighted material.

Under certain conditions specified in the law, libraries and archives are authorized to furnish a photocopy or reproduction.

One of three specified conditions is that the photocopy or reproduction is not to be used for any purpose other than private study, scholarship or research.

If electronic transmission of reserve material is used for purposes in excess of what constitutes “fair use”, that user may be liable for copyright infringement.

This policy is in effect for the following document:

Developmental and Lesion Effects in Brain Activation During Sentence Comprehension and Mental Rotation

James R. Booth

*Department of Communication Sciences and Disorders
Northwestern University*

Brian MacWhinney

*Department of Psychology
Carnegie Mellon University*

Keith R. Thulborn

*Center for Magnetic Resonance Research
University of Illinois at Chicago*

Kelley Sacco

*Department of Psychology
Carnegie Mellon University*

James T. Voyvodic

*Brain Imaging and Analysis Center
Duke University*

Heidi M. Feldman

*Department of Pediatrics
University of Pittsburgh*

The development of neurocognitive networks was examined in 2 cognitive paradigms: auditory sentence comprehension and mental rotation of alphanumeric stimuli. Patterns of brain activation were measured with whole brain echoplanar functional magnetic resonance imaging at 3 Tesla in 5 adults (20–28 years old), 7 children

(9–12 years old), and 6 pediatric patients (9–12 years old) with perinatal strokes or periventricular hemorrhages. Healthy children and adults activated similar neurocognitive networks, but there were developmental differences in the distribution of activity across these networks. In the sentence task, children showed more activation in the inferior visual area suggesting an imagery strategy rather than a linguistic strategy for sentence processing. Furthermore, consistent use of a sentence comprehension strategy, whether correct or incorrect as compared to chance performance, was associated with greater activation in the inferior frontal area (Broca's) in both children and pediatric patients. In the mental rotation task, healthy adults showed more activation in the superior parietal and middle frontal areas and less activation in the supramarginal gyrus, suggesting adults were primarily engaged in visual-spatial manipulation and less engaged in the recognition of noncanonical views of stimuli. The pediatric patients showed patterns of activation consistent with organization of cognitive processing into homologous areas of the contralateral hemisphere.

A central issue in research on recovery after brain injury is whether brain areas are equipotential or intrinsically specialized (Kaas, 1995; Kosslyn & Koenig, 1992; Lashley, 1933; Lenneberg, 1967; Van Kleek, 1989; Webster, Bachevalier, & Ungerleider, 1995). In general, research suggests that infants show more recovery following brain damage than older children and adults. However, this depends on the developmental status of the organism, the cognitive process being measured, and the neural structures under study (Finger, 1991; Hart & Faust, 1988; Kolb & Gibb, 1991; Schneider, 1979; Whishaw & Kolb, 1988). One way of exploring these issues of plasticity is to compare cognitive processing in healthy children to children with focal brain lesions.

Behavioral research on children with focal brain lesions has shown that language functions are preserved relative to spatial functions (Aram & Eisele, 1994; Bates et al., 1997; Muter, Taylor, & Vargha-Khadem, 1997; Stiles, Trauner, Engel, & Nass, 1997; Teuber & Rudel, 1962). One possible explanation for this sparing of language function is that, after injury to the left hemisphere, language functions organize to homologous areas in the contralateral hemisphere. If this is what happens, the result may be a certain cognitive crowding that compromises functions normally performed in that hemisphere, that is, visual-spatial processing (Papanicolaou, Discenna, Gillespie, & Aram, 1990). In the case of language processing, the hypothesis that functions served by damaged areas organize to contralateral, homologous areas is supported by at least two lines of evidence. First, there is evidence that adult stroke patients undergo a period of recovery that leads to increased activation bilaterally during auditory and language tasks (Engelien et al., 1995; Weiller et al., 1995). Second, functional magnetic resonance imaging (fMRI) studies with normal adults show that increasing task difficulty increases the magnitude of bilateral activation in homologous areas. This pattern has been documented for working memory, mental rotation, and language tasks (Braver et al., 1997; Carpenter, Just, Keller, Eddy, & Thulborn, 1999; Just,

Carpenter, Keller, Eddy, & Thulborn, 1996). Bilateral activation seems to be a general process in difficult, cognitive tasks suggesting that the relevant neural wiring may be in place in both hemispheres.

A hemorrhage or stroke also reduces the amount of neural tissue, so it is also possible that adjacent ipsilateral brain areas may be increasingly activated during cognitive operations (Ramachandran, 1993). Research with nonhuman primates has shown that bilateral ablation in infants causes ipsilateral brain regions at a considerable distance to take over function of the damaged area. For example, Webster et al. (1995) showed that if ventral temporal regions are removed bilaterally, then adjacent parietal regions, usually responsible for detection of motion and orientation, take over functions associated with object recognition. However, bilateral ablation of ventral temporal areas in adult monkeys results in pervasive deficits in object recognition. Like monkeys, human children with brain damage are likely to demonstrate a different kind of plasticity during recovery than adults. Young children have higher levels of brain glucose metabolism than adults (Chugani, Phelps, & Mazziotta, 1987). With development and presumably through a competitive process, certain synaptic connections are eliminated (Huttenlocher, 1990). These differences may allow for greater plasticity in children than in adults. In summary, the previous literature suggests that early brain injury may lead to the recruitment of contralateral homologous brain areas as well as local organization to ipsilateral adjacent areas.

In this study, fMRI techniques were used to examine the functional organization of cognitive processing in healthy adults, healthy children, and pediatric patients with strokes or periventricular hemorrhages (PVHs). This article provides direct evidence on how the human brain organizes in response to early injury (see also Muller, Rothermel, Behen, Muzik, Mangner, Chakraborty, & Chugani, 1998; Muller, Rothermel, Behen, Muzik, Mangner, & Chugani, 1998). Two extensively studied experimental tasks were used to investigate the functional organization of language processing and mental rotation. We expected these tasks to activate different cortical areas in two large-scale neurocognitive networks (Mesulam, 1998).

LANGUAGE PROCESSING

Language comprehension is a complex process involving speech perception as well as semantic and syntactic analysis. Many studies have shown that Broca's and Wernicke's areas are involved in language tasks (Demonet et al., 1992; Howard et al., 1992; Petersen & Fiez, 1993; Zurif & Swinney, 1994). Evidence also points to the importance of other areas in language processing. For example, imaging studies have implicated the anterior–superior temporal area in syntactic processing (Mazoyer et al., 1993; Vorob'ev et al., 1998). Imaging studies have also shown that the dorsolateral prefrontal cortex (DLPFC) is active during language and reading

tasks. The DLPFC may be responsible for modulation of processing in posterior semantic regions such as Wernicke's area (Frith, Friston, Liddle, & Frackowiak, 1991; Raichle et al., 1994) or for maintaining verbal information in memory (Jonides et al., 1997).

A sentence comprehension task was chosen as our experimental paradigm because it is a relatively natural linguistic task (Poeppel, 1996). The sentence task was based on a large-scale study (Booth, MacWhinney, & Harasaki, 2000) in which children read or listened to sentences and then responded true or false to a statement about each sentence. In general, children showed lower accuracy levels to difficult object-relative sentences, such as "The pig that the dog followed ate the trash in the street." They showed middle accuracy levels to moderate subject-relative sentences, such as "The principal that tripped the janitor used the phone to call home." They showed higher accuracy levels to easier conjoined verb-phrase sentences, such as "The cat chased the rabbit and enjoyed the hunt in the yard." Past imaging studies on reading have shown that difficult sentences activate more cortical area than easy sentences (Just et al., 1996). One goal of this study was to determine if more cortical area is activated when attempting to comprehend difficult sentences that are presented auditorily.

In the Booth et al. (2000) sentence task, the true-false statements either tested for the subject of the first verb, for example, "The dog followed the pig," or the subject of the second verb, for example, "The principal used the phone." Children showed lower accuracy levels on second verb questions because a correct answer requires them to draw a subject-verb dependency across an intervening clause, whereas the first verb questions do not. Further analyses indicated different accuracy patterns for children who comprehended the sentences at above chance levels and for noncomprehenders. Noncomprehenders consistently answered the second verb questions at below chance levels. For example, after the object-relative sentence, "The pig that the dog followed ate the trash in the street," they often responded true to the statement, "The dog ate the trash." Their answers were based on an incorrect local attachment strategy that treated the second noun as the subject of the second verb. The consistency of the noncomprehender's responses established that these children were in fact processing language, but their ineffective strategy provided them with incorrect answers. Thus, another goal of our imaging study was to determine if these strategies were associated with different amounts of activation.

MENTAL ROTATION

One of the most studied visual-spatial manipulation tasks is mental rotation. Shepard and Metzler (1971) showed that a participant's response time for a correct judgment was a linear function of degree to which they had to rotate the stimuli.

Mental rotation involves at least four different processes: (a) encoding and recognizing a visual stimulus, (b) rotating a stimulus by visualization into the proper orientation, (c) holding the mentally rotated stimulus in spatial working memory, and (d) making a judgment as to whether the stimulus is the same as or different from a comparison stimuli (or forward or backward depending on the task).

It is likely that several different brain areas are required to perform a mental rotation task. First, the recognition of visual stimuli, particularly for objects or familiar shapes, is thought to involve the inferior occipital temporal pathway or the “what” system (Mishkin, Ungerleider, & Macko, 1983; Ungerleider & Haxby, 1994). Second, the actual mental rotation of stimuli is thought to involve the occipital parietal pathway or the “where” system. Several imaging studies with adults now show that mental rotation produces robust activation in parietal regions (Alivisatos & Petrides, 1997; Cohen et al., 1996), and lesion studies show parietal damage affects performance on visual-spatial tasks such as mental rotation (Newcombe & Ratcliff, 1989). Furthermore, greater angular disparities and error rates are associated with a larger area of significant activation in the superior parietal region (Carpenter et al., 1999; Tagaris et al., 1997), suggesting that this area is directly involved in mental rotation. Based on these studies, we expected to see the most pronounced developmental differences during the mental rotation task in the superior parietal region. Third, the temporary storage of the rotated stimuli should be associated with activation in prefrontal regions that have been shown to be involved in spatial working memory (Jonides et al., 1993).

THIS STUDY

There were three main goals of this research project. The first goal was to delineate developmental differences in the distribution of activity in large-scale neurocognitive networks for sentence processing and mental rotation. The second goal was to examine the relation of strategy use during the sentence tasks to patterns of brain activation. The third goal was to determine whether pediatric patients show patterns of activation consistent with organization of cognitive processing in homologous areas in the intact hemisphere.

METHOD

Participants

All participants were native English speakers. Informed consent was obtained from all individuals with an experimental protocol approved by the University of Pittsburgh Institutional Review Board and in compliance with the Code of Ethics of the

World Medical Association. There were two healthy participant groups in this study: five right-handed adults (20–28 years old) and seven right-handed children (9–12 years old). Handedness was determined by the Edinburgh inventory (Oldfield, 1971). All adults and parents of children were screened with an informal interview to make sure participants had no self-reported history of (a) language, reading, or learning disabilities; (b) behavior or attention problems; or (c) hearing or vision deficits.

There were also six pediatric patients who experienced a brain injury within the first year of life (SJ, BR, MK, MM, GM, DK). The patients fell into two different groups: cerebral infarct (CI) or PVH. CI or stroke damages discrete or focal areas of cortical gray matter and underlying white matter of the brain that is fed by a particular branch of a cerebral artery. In contrast, PVH involves primarily an injury to subcortical white matter with less damage to the cortical mantle. Table 1 presents demographic and medical information for the six pediatric patients. All but one of the pediatric patients were left-handed. The healthy population groups were chosen to be right-handed because of the high probability that most of the pediatric patients would have developed right-handedness if they had not experienced damage to their left hemisphere.

The following brain areas were preserved in SJ: medial posterior occipital lobe, posterior inferior temporal gyrus, posterior occipital temporal gyrus, medial orbital gyrus, medial frontal pole, anterior–superior frontal gyrus, and anterior middle frontal gyrus. Damage to the occipital lobe resulted in a small scotoma. We described the preserved areas in SJ because of the extensive damage to the left hemisphere.

The following left hemisphere brain areas were damaged in BR: parts of the inferior and middle frontal gyri including Broca's area and the DLPFC (Brodmann's Areas [BA] 44, 45, 46, and 47).

The following left hemisphere brain areas were damaged in MK: the superior portion of the superior temporal gyrus, most of the angular gyrus and

TABLE 1
Demographic and Medical Data for the Six Pediatric Patients

<i>Patients</i>	<i>Gender</i>	<i>Age^a</i>	<i>Hemisphere of Lesion</i>	<i>Handedness</i>	<i>Lesion Type</i>
SJ	Male	12	Left	Left	CI
BR	Male	9	Left	Left	CI
MK	Female	11	Left	Left	CI
MM	Female	9	Left	Left	PVH
GM	Male	12	Left	Left	PVH
DK	Female	10	Right	Right	CI

Note. CI = cerebral infarction; PVH = periventricular hemorrhage.

^aAge at time of functional magnetic resonance imaging. Standardized cognitive tasks were administered at 6 months, at the least.

supramarginal gyrus, the inferior portion of the inferior frontal gyrus, and inferior portions of the precentral and postcentral gyrus.

MM had a PVH adjacent to the left lateral ventricle. This lesion spanned from $z = 28$ to $z = 50$ with an axial center point of $x = -30$ and $y = 18$ (Talairach & Tournoux, 1988). This lesion included damage to the frontal eye fields and to interior white matter (corona radiata, centrum semiovale, and corpus callosum). There was also evidence of a slight enlargement of the fourth ventricle in both hemispheres.

GM also had a PVH adjacent to the left lateral ventricle. This lesion spanned from $z = 28$ to $z = 40$ with an axial center point of $x = -25$ and $y = 20$ (Talairach & Tournoux, 1988). This lesion included damage to the frontal eye fields and to the interior portion of the central sulcus and parietal areas. There was also evidence of a slight enlargement of the fourth ventricle in both hemispheres.

The following brain areas were damaged in DK: the right parietal area including parts of the angular gyrus (BA 40) and supramarginal gyrus (BA 39).

Standardized Measures

Each pediatric patient was given a battery of standardized cognitive processing measures. These measures included a nonverbal intelligence test (Leiter, 1980), an untimed receptive picture vocabulary test (Dunn & Dunn, 1981), and two language processing subtests on the Clinical Evaluation of Language Function—Revised (Semel, Wiig, & Secord, 1989). The Formulating Sentences subtest required the patients to generate a sentence when given individual words or three-word phrases. The Recalling Sentences subtest required the patients to recall and reproduce sentences of varying length and syntactic complexity.

Each pediatric patient was also administered a battery of reading measures on a computer with the PsyScope experimental presentation software program (Cohen, MacWhinney, Flatt, & Provost, 1993). The Word Identification test (Woodcock, 1987) requires participants to read aloud words of increasing difficulty (e.g., *is*, *zeitgeist*). The Phonetic Analysis test (Bjom, Madden, & Gerdner, 1984) requires participants to decide which word among three words, such as *graph*, *right*, and *group*, contains the sound of an underlined letter (or letters) in another word, such as *foam*. The Word Attack test (Woodcock, 1987) requires participants to name nonwords of increasing difficulty (e.g., *dat*, *byrcal*). The Orthographic Choice test (Olson, Kliegl, Davidson, & Foltz, 1985) requires participants to decide which of two spellings is correct (e.g., *bean* or *bene*, *tortace* or *tortoise*). The Exception Words test (Adams & Huggins, 1985) requires participants to read aloud exception words of increasing difficulty (e.g., *ocean*, *baroque*). Each pediatric patient was also administered an Auditory Digit Span test.

Each pediatric patient was compared to an age-matched control population of at least 20 children for the digit span and reading measures. Z scores were computed

for each pediatric patient to determine if they had a cognitive deficit relative to their peers.

fMRI Cognitive Tasks

All cognitive tasks were projected into the magnetic resonance (MR) environment with the functional imaging software program CIGAL (Voyvodic, 1999).

Sentence processing. Each sentence was presented through earphones. There were three sentence types that ranged in complexity from harder object-relative sentences, to moderate subject-relative sentences, to easier conjoined verb-phrases (see Figure 1). All of these sentences were controlled for lexical characteristics. After listening to each sentence, the participant was asked to answer a true–false statement by pressing an appropriate button. The question either tested for the subject of the first verb or the subject for the second verb (refer to the earlier discussion of this topic). During each trial, the participant heard a 1,000

THREE SENTENCE TYPES

EASY

Conjoined-verb-phrase: The cat chased the rabbit and enjoyed the hunt in the yard

MEDIUM

Subject-relative: The principal that tripped the janitor used the phone to call home

DIFFICULT

Object-relative: The pig that the dog followed ate the trash in the street

ANGULAR DISPARITIES FOR LETTER “G”

0°	135°	180°	225°
G	⌚	Ⓜ	⌚
Ⓜ	⌚	Ⓜ	⌚

FIGURE 1 Sample stimuli for the sentence processing (top) and mental rotation (bottom) experimental paradigms.

msec warning signal (i.e., “listen”) followed by a sentence presented during a 6,500 msec interval, and then they heard a 1,000 msec warning signal (i.e., “question”) followed by a question presented during a 6,500 msec interval. Each of the nine experimental blocks (60 sec each) contained four sentences of the same type (three blocks for each sentence type), and these were interleaved with nine rest blocks consisting of a visual fixation cross (40 sec each). The entire experimental paradigm lasted 15 min.

Mental rotation. In the mental rotation task, participants were asked to mentally rotate a letter or number (2,5,7, G, F, R) to its upright position and to determine, after rotating, whether the letter or number was forward or backward (Alivisatos & Petrides, 1997, see Figure 1). The individual was asked to press an appropriate button to indicate his or her answer. Each of the six experimental blocks (72 sec each) contained 24 stimuli presented for 3 sec each, and these were interleaved with six rest blocks consisting of a visual fixation cross (40 sec each). The entire experimental paradigm lasted 11.2 min. The stimuli were presented at four different orientations (0°, 135°, 180°, and 225° from upright).

We used a low-level baseline task because we wanted to see all of the relevant areas of the brain that were activated during language comprehension and mental rotation. A simple baseline condition was chosen because of the controversy concerning the subtraction method (Poeppel, 1996). The role of inhibitory mechanisms in patterns of brain activation is presently unclear. If a baseline condition either inhibits or activates a particular brain area thought to be involved in the experimental task, this would overestimate or underestimate, respectively, the degree of activation in the experimental task. Furthermore, when examining developmental differences or patient population differences, it may be hard to interpret the pattern of activation from a high-level subtraction, because participants may be using different strategies for processing the baseline task.

Magnetic Resonance Imaging (MRI) Procedure

All individuals participated in a 1-hr practice session at least 1 day before the fMRI procedure. After a debriefing on the experimental procedure, the adult participants were asked to sign the consent form, and parents were asked to sign the consent form for the child participants. Then the participants practiced a shortened version of each cognitive task on a computer. Different stimuli were used in practice and test sessions.

If this was an individual’s first MRI procedure, they were acclimated to the scanner environment in a simulator immediately before the scan. The simulator has been shown to reduce anxiety associated with being put in the MR scanner

(Rosenberg et al., 1997). No sedation was used for children or adults. After entering the MR scanner environment, the participant's head was immobilized by a specially designed foam pillow including a pair of earphones. Sound was transmitted from computer to earphones via plastic tubing. The sound system allowed the participant to clearly hear each word in each sentence, despite the loud scanner noise. An optical button box was placed in the right, dominant hand of healthy adults and children, and in the left, dominant hand for five of six pediatric patients. The dominant hand was used for pediatric patients because the pace of the cognitive paradigms was rather quick and we wanted an accurate measure of reaction time.

All images were acquired using a 3.0-T GE Medical Systems scanner at the Magnetic Resonance Research Center of the University of Pittsburgh Medical Center. This machine provides a homogeneous signal throughout the entire cortex. Blood oxygenation level-dependent (BOLD) gradient echoplanar fMRI with a head coil was used for all functional scans. Functional images were acquired at a repetition time (TR) of 4,500 msec in 21 axial or oblique axial slices. The slices covered most of the brain except for the superior portion of the central sulcus (including superior portion of BA 1, 2, 3, 4, and 5) and the inferior portion of the temporal lobe (including inferior portion of BA 20, 36, and 38). Because of artifacts created by the eye orbits, the orbital region of the frontal lobes was not included in any analyses (BA 11 and 47). The following scan parameters were used: time of echo (TE) = 25 msec, flip = 90°, field of view = 400 mm × 200 mm, slice thickness = 3 mm, slice gap = 1 mm, acquisition matrix = 128 × 64, and voxel size = 3.1 mm × 3.1 mm × 3 mm. High-resolution, T1-weighted, spoiled gradient (SPGR) echo scans (axial SPGR) were acquired for anatomical localization. T1 is the longitudinal relaxation time that characterizes the time required for a nuclear spin system to reach its new equilibrium orientation when an external magnetic field is applied. The following scan parameters were used: TR = 25 msec, TE = 4 msec, flip = 40°, acquisition matrix = 256 × 192, number of slices = 124, and field of view = 240 mm × 180 mm.

Data Analysis

In-plane (x, y) head movement for the functional scans was determined by FIASCO, which is functional imaging analysis software (Eddy, Fitzgerald, Genovese, Mockus, & Noll, 1997). After this procedure, 10 out of 14 data files for children (5 for sentence task and 5 for mental rotation task) exhibited acceptable levels of motion (less than 1 mm). All 10 data files for adults (5 adults in two cognitive tasks) exhibited acceptable levels of motion. For the six pediatric patients, 11 out of 12 data files exhibited acceptable levels of motion. The mental rotation data set for BR were not useable due to excessive movement. For useable data sets, the mean of maximum head motion across participants was less than 0.47 mm, and maximum movement within participants was less than 0.81 mm. All inferential analyses reported later were based on at least five individuals per group.

Before functional activation maps were produced, all functional data were detrended to eliminate slow fluctuations in signal using the FSCAN program (Voyvodic, 1999). A voxel was considered active if a *t* test comparing activation in the experimental condition to the rest condition was above a threshold value ($t > 5.0$). The same threshold was used for all participants. In addition, an area was not considered active unless two adjacent voxels in the *x-y* plane were above the threshold value. Adjacency was defined as voxels touching on the sides or corners. To determine the location of each activated voxel, we superimposed the functional activation images onto the high resolution structural images using analysis of functional neuroimaging (AFNI; Cox, 1996). We then calculated the number of activated voxels in each region of interest (ROI; discussed later).

Morphometry

To obtain a more quantitative description of lesion morphology in the pediatric patients, image data from the T1-weighted MRI scans were examined using the Alice image processing program (Hayden Image Processing Group, 1997). Volume analysis for the left and right cerebral cortex was computed from 22 axial slices. The segmentation process yielded three volume estimates: lesion volume, volume of remaining tissue in lesioned hemisphere, and volume of nondamaged hemisphere. Only cortical tissue was included in the volumetric analysis. From these estimates, we calculated a left-right volume ratio by dividing the volume of the left hemisphere by the volume of the right hemisphere (see Table 2). This ratio reflects the amount of damage to the injured hemisphere relative to the intact hemisphere.

RESULTS

Standardized Cognitive Measures

Table 2 presents the standardized scores on cognitive measures and the left-right ratio for each pediatric patient. For a graphical representation of lesion size, refer to Figure 2, which presents sagittal slices through the injured hemisphere for the six pediatric patients. To determine whether lesion size was related to cognitive task performance, we computed correlation coefficients between the left-right volume ratio and standardized scores. Three general findings emerged. First, nonverbal intelligence and receptive vocabulary scores were in the normal range (except for GM), and these scores were not related to lesion size. This indicates that these children did not have a pervasive intellectual deficit and is consistent with other studies showing that children with early focal lesions are relatively high functioning (Bates et al., 1997). Second, children with larger lesions to the left hemisphere had lower scores on reading tasks than children with smaller lesions. It may be that later acquired cognitive skills, such as reading, benefit little from early developmental

TABLE 2
Scores for the Patients on the Standardized Cognitive Measures and Correlation of Scores With Size of Lesion

<i>Cognitive Task</i>	<i>Patients</i>						
	<i>SJ (0.44)^a</i>	<i>MK (0.70)</i>	<i>BR (0.82)</i>	<i>MM (0.93)</i>	<i>GM (0.98)</i>	<i>DK (1.0)</i>	<i>Left/Right Correlation^a</i>
General							
Receptive vocabulary ^b	100.00	97.00	98.00	95.00	125.00	98.00	.30
Nonverbal intelligence ^b	103.00	107.00	92.00	121.00	66.00	107.00	-.20
Reading							
Word identification ^c	-5.22	-1.84	-1.28	-1.44	0.89	-0.75	.92**
Word attack ^c	-3.26	-0.85	-1.26	-0.70	0.18	0.17	.83*
Exception words ^c	-3.73	-1.36	-1.30	-1.64	1.38	-0.56	.94**
Phonetic analysis ^c	-5.38	-0.38	-1.08	-0.48	0.86	0.48	.91*
Orthographic choice ^c	-3.07	-1.15	-0.71	-0.20	-0.53	-1.08	.87*
Memory							
Auditory digit span ^c	-2.35	-1.30	-1.09	-0.10	0.94	-0.10	.90*
Language							
Recalling sentences ^d	3.00	6.00	7.00	7.00	11.00	11.00	.92**
Formulating sentences ^d	3.00	6.00	4.00	6.00	4.00	4.00	.28

^aRatio of left brain volume over right brain volume. ^bStandard scores from standardized norms. ^cZ scores based on at least 20 control children. ^dStanines from standardized norms.

* $p < .05$. ** $p < .01$.

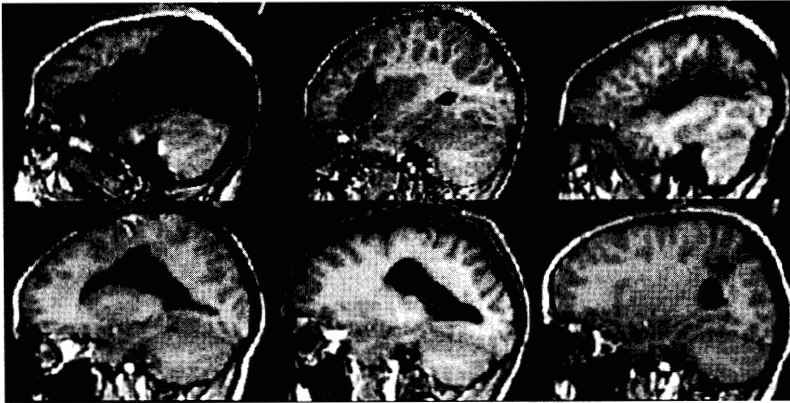


FIGURE 2 Sagittal slices through the injured hemisphere of the pediatric patients. From left to right and top to bottom: SJ, BR, MK, MM, GM, and DK. A slice was chosen to illustrate the maximum extent of the lesion. All slices are through the left hemisphere except for DK. Axial slices of each individual are displayed in the activation maps in Figures 4 and 7.

plasticity. Third, only language tasks that involved a large memory component were related to lesion size. In particular, Recalling Sentences and Auditory Digit Span were related to lesion size but Formulating Sentences was not. In sum, these analyses suggest that the severity of impairment in word recognition skills and language tasks involving a memory component is related to lesion size.

ROI

For group data analysis, we defined ROI and then averaged activation data within individuals. This technique takes advantage of the high resolution of fMRI at the individual level and ensures that comparable ROIs are averaged across participants (Steinmetz & Seitz, 1991; Tootell et al., 1995). Table 3 lists the 17 ROIs and their corresponding BA (see Figure 3 for graphical representation). The anterior temporal ROIs were defined as greater than 20 mm, and posterior temporal ROIs were defined as less than 20 mm in the y plane (Talairach & Tournoux, 1988). The superior visual association ROI was defined as above 5 mm, and inferior visual association ROI was defined as below 5 mm in the z plane (Talairach & Tournoux, 1988).

Percentage Signal Change

There were no significant differences ($t_s < 1$) in percentage signal change between the sentence processing and mental rotation tasks for adults (1.05 vs. 1.53), children

TABLE 3
Seventeen Regions of Interest and Their Brodmann's Areas

<i>Regions of Interest</i>	<i>Brodman's Areas</i>
Frontal	
Central sulcus, anterior	4, 6
Middle frontal	8, 9
Prefrontal	10, 46
Broca's area	44, 45
Parietal	
Central sulcus, posterior	1, 2, 3
Superior parietal	5, 7
Angular gyrus	39
Supramarginal gyrus	40
Temporal	
Heschl's gyrus	41, 42
Superior temporal, anterior	22
Superior temporal, posterior	22
Middle temporal, anterior	21
Middle temporal, posterior	21
Inferior temporal	20, 37
Occipital	
Superior visual association	18, 19
Inferior visual association	18, 19
Cingulate	
Anterior cingulate	24, 32

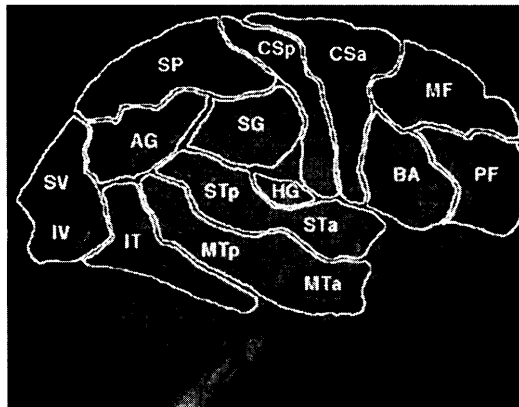


FIGURE 3 Sixteen of the 17 regions of interest. The anterior cingulate cannot be presented in a lateral view of the brain. *Note.* The picture of the brain is from *Digital Anatomist: Interactive Brain Atlas*, by J. W. Sundsten, 1994, Seattle, WA: Health Sciences Center for Educational Resources, University of Washington. Copyright 1994 by the University of Washington. Reprinted with permission.

(1.38 vs. 1.70), or pediatric patients (1.58 vs. 1.66). In addition, there were no significant differences between healthy children and adults or pediatric patients ($t_s < 1$). Because the percentage signal change results show no significant differences, the sensitivity of BOLD contrast does not appear to change between paradigms or populations. Therefore, it is reasonable to assume that any differences in patterns of activation can be interpreted as decreased neuronal activity and not differences in blood circulation. In addition, it is reasonable to use t thresholds to compare patterns of brain activation.

Sentence Processing

Behavioral outcomes. The adults showed significantly lower accuracy levels for harder object-relative sentences than for moderate subject-relative sentences or for easy conjoined verb-phrase sentences ($p_s < .05$; see Table 4). These results are generally consistent with other studies using similar sentence types with adults (King & Just, 1991).

The pattern of results for pediatric patients was similar to healthy children. Both exhibited lower accuracy levels than adults and no clear sentence type differences in accuracy. Both groups of children may have exhibited no sentence type differences because all sentences were relatively hard for them to comprehend. At the individual level, all patients scored above chance levels on at least one of the sentence types, suggesting that they were cognitively engaged in the language task. In fact, three patients (MK, MM, and DK) scored below chance (< 40%) on at least one sentence type. Booth et al. (2000) showed that healthy children who score below chance are often using an incorrect local attachment strategy. Children who score below chance levels are clearly engaged in the linguistic task because they are consistently applying a strategy. The low scores for children may result from their incorrect, but consistent, use of a local attachment strategy.

TABLE 4
Error Rates and Number of Areas Activated as a Function of Sentence Type

Participants	Error Rates ^a			Number Areas		
	CVP	SS	SO	CVP	SS	SO
Adults	11	7	18	3.22	2.73	3.59
Children	36	32	36	1.82	1.87	1.81
Pediatric patients	42	51	42	1.57	1.70	1.72

Note. CVP = conjoined verb phrase; SS = subject relative; SO = object relative.

^aNumbers are given in percentages.

Patterns of activation. Figure 4 displays functional activation images coregistered on high resolution structural images for the sentence task. The panels for the healthy adults and children are group data created in AFNI (Cox, 1996), whereas the panels for the pediatric patients are individual data. Figure 5 displays a quantification of the mean percentage of total voxels activated in each ROI in each hemisphere for adults, children, and pediatric patients.

The following analysis procedure was used for the sentence processing and mental rotation data. We first present results that compare patterns of brain activation in healthy children and adults, and then we present analyses that compare pediatric patients to healthy children. Finally, we examine the relation between accuracy on the experimental task and patterns of brain activation. There were two dependent variables in the inferential analyses: percentage of total voxels and number of activated areas. Number of activated areas refers to the number of distinct or noncontiguous areas within a ROI. Because percentage and number were moderately correlated, $r(1,054) = .57, p < .001$, we only present new information provided by the number of activated areas analyses.

Healthy adults and children. An analysis of variance (ANOVA) on percentage of activated voxels with hemisphere (right, left), ROI (17 regions), and age (children, adults) as independent variables showed significant main effects for ROI, $F(16, 340) = 4.12, p < .001$; and hemisphere, $F(1, 340) = 8.72, p < .01$. The main effects established that the sentence task produced more activation in the left

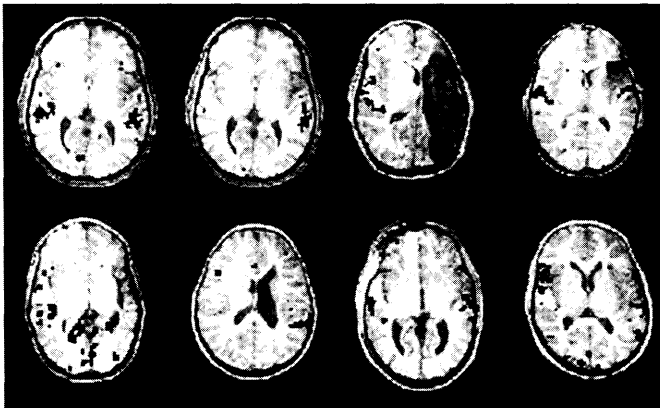


FIGURE 4 Functional activation ($t > 5.0$) superimposed on high resolution structural images for the sentence task. From left to right and top to bottom, the panels represent one axial slice of group data for healthy adults, healthy children, and individual data for each pediatric patient in the following order: SJ, BR, MK, MM, GM, and DK. The slice for each participant is through the superior temporal area (Brodmann's Areas 21, 22).

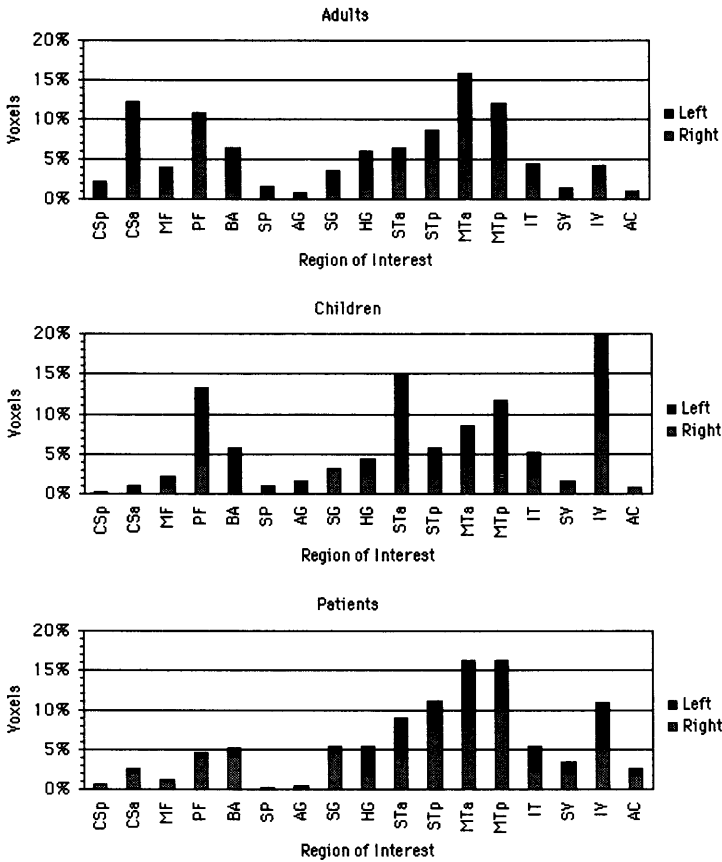


FIGURE 5 Percentage of total voxels activated in each region of interest (see Table 3 and Figure 3) in the right (gray) and left hemispheres (black) for the sentence task. Data represent means for healthy adults (out of 599 voxels), healthy children (out of 220 voxels), and pediatric patients (out of 287 voxels).

hemisphere than in the right hemisphere, and produced the greatest activation in superior temporal, middle temporal, inferior frontal, prefrontal, and anterior central sulcus regions. This ANOVA also showed a significant interaction between ROI and age, $F(16,340) = 1.82, p < .05$. Only differences between the adults and children of greater than 5% are mentioned here. This interaction resulted mainly from the fact that children exhibited more activation in the inferior occipital area and the anterior superior temporal area, whereas the adults produced more activation in the region anterior to the central sulcus and the anterior middle temporal area. In addition, an ANOVA on number of activated regions showed a significant main effect

of age, $F(1, 340) = 19.70, p < .001$. The main effect for age established that there were more distinct areas of activation in adults than in children.

Children versus pediatric patients. Although etiology and site of lesion varied for each pediatric patient, we wished to compare, as a whole, children with brain lesions to healthy children. To do this, we calculated an ANOVA on percentage of activated voxels with hemisphere (right, left), ROI (17 regions), and group (children, patients) as independent variables. This analysis showed a significant main effect for ROI, $F(16, 374) = 5.02, p < .001$, as well as an interaction between hemisphere and group, $F(1, 374) = 9.54, p < .01$. The significant interaction between hemisphere and group showed that healthy children primarily activated a left hemisphere network during the sentence task, whereas the pediatric patients primarily activated a right hemisphere network (see Figures 4 and 5). Although the interaction between group and ROI was not significant, it is interesting to note that the healthy children showed more activation in prefrontal regions than the pediatric patients.

Relation of accuracy to brain activation. To examine the relation between sentence comprehension accuracy and brain activation, we calculated correlations of question accuracy with percentage of total voxels for the 17 ROIs for the left and right hemisphere. We calculated these correlations including healthy children and adults partialling for age, so that the correlations can be attributed to accuracy and not age differences. Because of the large number of correlations (34), we set the significance value at $p < .005$. There were no significant relations between accuracy and activation, so the developmental age effects previously described may not be accounted for by accuracy differences.

Relation of sentence type to brain activation. We also examined patterns of activation for each sentence type, because accuracy levels on this task varied considerably. We calculated an ANOVA on number of activated areas with sentence type (conjoined verb-phrase, subject-relative, and object-relative), hemisphere (right, left), ROI (17 regions), and group (adults, children, patients) as independent variables. Only effects involving sentence type are presented, because the effects involving the other variables were mentioned earlier. The ANOVA produced a significant interaction between sentence type and group, $F(4, 1,632) = 3.43, p < .01$. The adults showed a greater number of areas for difficult object-relative sentences than for moderate subject-relative sentences or for easy conjoined verb-phrase sentences (see Table 4). In contrast, the children and pediatric patients activated about the same number of areas for the three sentence types.

As previously discussed, there are behavioral differences in children's strategies for comprehending complex sentences with multiple clauses (Booth et al., 2000). We examined brain activation differences between participants who comprehended below chance (< 40%) versus those who comprehended at chance (40%-60%) ver-

sus those who comprehended above chance levels (> 60%). We could not examine age differences in comprehension accuracy because all adults scored at above chance levels, so we examined only comprehension accuracy differences in children and pediatric patients. An ANOVA on percentage of activated voxels with hemisphere (right, left), ROI (17 regions), and comprehension (below chance, at chance, above chance) as independent variables showed a significant interaction between ROI and comprehension, $F(32, 340) = 2.16, p < .01$. Only differences greater than 4% between the groups are mentioned here (see Figure 6). Children who scored above and below chance activated the inferior frontal region more and Heschl *gyrus* less than children who scored at chance levels. In addition, children who scored at chance levels showed more activation in middle temporal, whereas children who scored above chance showed more activation in superior temporal.

Mental Rotation

Behavioral outcomes. Table 5 presents means for accuracy and reaction time on the four different rotation orientations for adults, children, and pediatric patients. The means for all participant groups were as predicted (Shepard & Metzler, 1971). Accuracy and reaction time were a function of the angular difference between the letter or number and its upright position. Accuracy levels were highest and reaction times were fastest for the 0° condition, whereas accuracy levels were lowest and reaction times were slowest for the 180° condition. Accuracy levels and reaction times were in the middle for the intermediate 135° and 225° conditions.

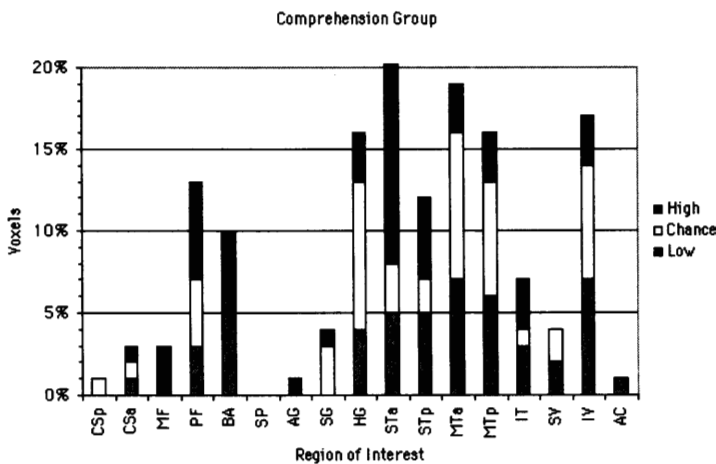


FIGURE 6 Percentage of total voxels activated in each region of interest for children scoring above chance (high), at chance (chance), and below chance (low) in the sentence task.

TABLE 5
Accuracy and Reaction Time for the Four Different Angular Disparities on
the Mental Rotation Task for Adults, Children, and Pediatric Patients

Participants	Angular Disparities							
	Accuracy ^a				Reaction Time ^b			
	0°	225°	135°	180°	0°	225°	135°	180°
Adults	87	85	78	75	2,035	2,169	2,178	2,448
Children	87	81	76	70	2,171	2,334	2,460	2,527
Pediatric patients	79	67	69	63	2,242	2,270	2,291	2,386

^aNumbers are given in percentages. ^bNumbers given in milliseconds.

The individual data for the pediatric patients showed that all patients scored above chance (> 60%) on at least one of the orientations. This suggests that all patients were cognitively engaged in the mental rotation task. It is interesting to note that SJ performed poorly on the mental rotation task and also exhibited the fewest number of activated voxels. This is consistent with other studies that have found preserved language functioning relative to visual-spatial functioning in children with brain lesions (Aram & Eisele, 1994; Bates et al., 1997; Muter et al., 1997; Stiles et al., 1997). GM exhibited the second lowest overall score on the mental rotation task. GM also scored very low on the Leiter (1980) intelligence scale, which is a nonverbal test that requires visual-spatial processing. GM's poor performance on these visual-spatial manipulation tasks may be a result of damage to white matter in the parietal area.

Healthy adults and children. An ANOVA on percentage of activated voxels with hemisphere (right, left), ROI (17 regions), and age (children, adults) as independent variables showed a significant main effect for ROI, $F(16,340) = 8.17$, $p < .001$. The main effect of ROI established that the mental rotation task produced the greatest activation in superior parietal, supramarginal gyrus, inferior visual, inferior temporal, and the region anterior to the central sulcus (see Figures 7 and 8). In addition, an ANOVA on number of activated regions showed significant main effects for age, $F(1,340) = 57.25$, $p < .001$, as well as an interaction between ROI and age, $F(16,340) = 2.11$, $p < .01$. The main effect for age established that there were more distinct areas of activation in adults than in children. Only differences greater than 5% between the adults and children are mentioned here (see Figure 8). Adults showed more activation in the superior parietal and middle frontal, whereas children showed more activation in the supramarginal gyrus.

Children versus pediatric patients. We calculated an ANOVA on percentage of activated voxels with hemisphere (right, left), ROI (17 regions), and

group (children, patients) as independent variables. This analysis showed significant main effects for ROI, $F(16, 340) = 5.27, p < .001$; and for hemisphere, $F(1, 340) = 6.36, p < .01$. In addition to these main effects, there was a trend for a significant interaction between hemisphere and group, $F(1, 340) = 2.92, p = .08$. The interaction between hemisphere and group suggests that healthy children activated a bilateral network during the mental rotation task, whereas the pediatric patients primarily activated a right hemisphere network (see Figures 7 and 8). Although the interaction between group and ROI was not significant, it is interesting to note that the pediatric patients showed more activation in anterior cingulate than healthy children. A recent study showed that higher error rates are associated with greater activity in the anterior cingulate region (Carter et al., 1998). Carter et al. interpreted these findings as suggesting that the anterior cingulate is involved in error detection and performance monitoring.

Relation of accuracy to brain activation. To examine the relation between mental rotation accuracy and brain activation, we calculated correlations of accuracy with percentage of total voxels for the 17 ROIs for the left and right hemisphere. We calculated these correlations including healthy children and adults partialling for age, so that the correlations can be attributed to accuracy and not age differences. Because of the large number of correlations (34), we set the significance value at $p < .005$. There were no significant relations between accuracy and activation, so the developmental effects previously described may not be accounted for by accuracy differences.

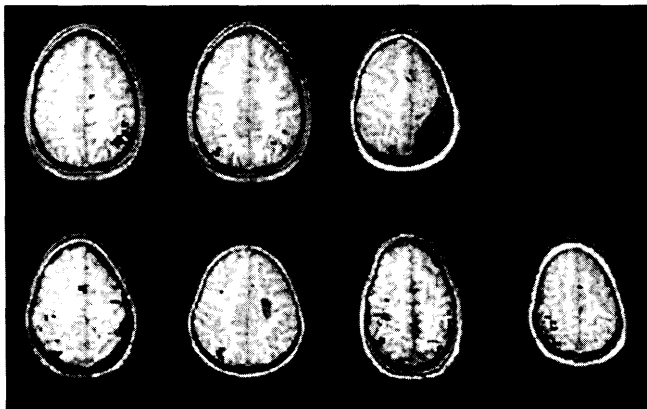


FIGURE 7 Functional activation ($t > 5.0$) superimposed on high resolution structural images for the mental rotation task. From left to right and top to bottom, the panels represent one axial slice of group data for healthy adults, healthy children, and individual data for each pediatric patient in the following order: SJ, BR, MK, MM, GM, and DK. The slice for each participant is through the superior parietal area.

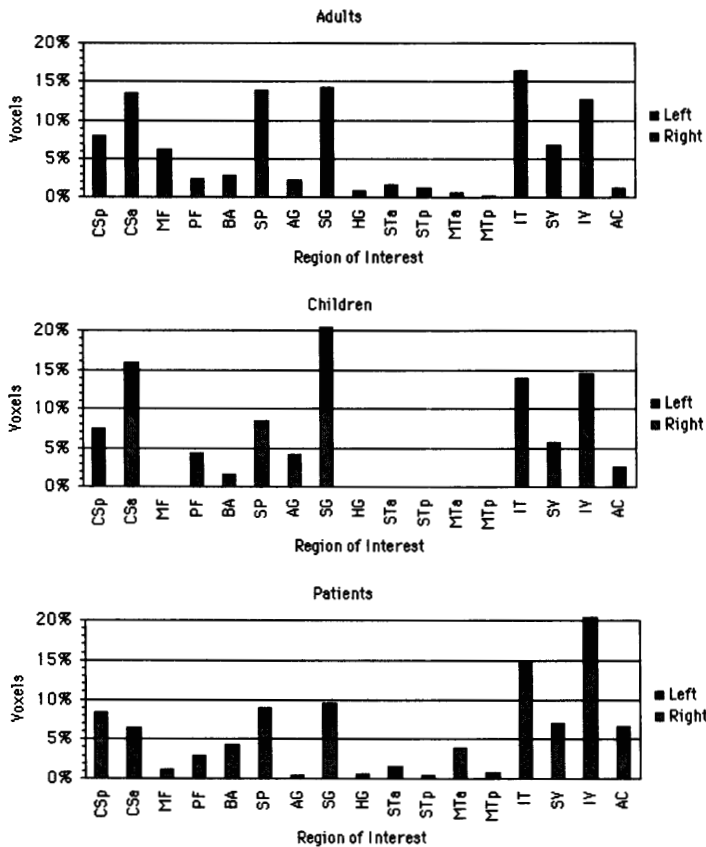


FIGURE 8 Percentage of total voxels activated in each region of interest (see Table 3 and Figure 3) in the right (gray) and left hemispheres (black) for the mental rotation task. Data represent means for healthy adults (out of 774 voxels), healthy children (out of 112 voxels), and pediatric patients (out of 157 voxels).

DISCUSSION

Developmental Effects in Sentence Processing in Intact Populations

The sentencetask activated a neurocognitive network involving bilateral regions in the temporal lobe, including parts of Wernicke’s area and regions in the left inferior frontal lobe, including parts of Broca’s area. These findings are consistent with past imaging studies with adults (Bavelier et al., 1997; Binder et al., 1997; Just et al.,

1996). Our finding that activation was not confined to traditional Wernicke's and Broca's areas is consistent with other studies that have shown that language is distributed across the temporal and frontal areas (Dronkers, Redbern, & Ludy, 1995; Ojemann, 1991). Our sentence task produced activation in prefrontal areas including DLPFC (Petersen & Fiez, 1993). Activation in the prefrontal area is consistent with the hypothesis that our sentence task involved memory processes. Auditory sentence processing may put greater demands on working memory than visual sentence processing because of the serial nature of spoken language. In addition, we found that activation in each ROI for the sentence task, as well as for the mental rotation task, consisted of many small areas, suggesting that cognitive networks consist of many focal regions that are distributed across the cortex (Bavelier et al., 1997).

One of the striking findings in our study was the extent of bilateral activation during the sentence task. These results are consistent with the view that most cognitive processes utilize bilateral brain regions, but that one hemisphere may be dominant (Kosslyn & Koenig, 1992; Lenneberg, 1967). The finding of extensive bilateral activation in our sentence task is in contrast to the notion of rigid lateralization (Kinsbourne & Hiscock, 1987; Van Kleek, 1989). We may have found a large amount of bilateral activation because of the cognitive difficulty of the sentence task or because of the increased sensitivity of BOLD contrast in fMRI at 3 Tesla (Carpenter et al., 1999; Thulborn, Davis, Erb, Strojwas, & Sweeney, 1996).

Although children and adults activated a similar neurocognitive network, there were three main developmental differences in the distribution of activity across that network in the sentence task. The first difference was that adults showed more areas of activation than children. Adults showed about equal amounts of activation in the left and right hemispheres, whereas children were left lateralized in their patterns of activation in the superior and middle portions of the temporal lobe. Adults may have had higher accuracy levels on the sentence task because they were more successful at recruiting the right hemisphere for language comprehension. The right hemisphere appears to be important for making inferences and understanding complex syntactic structures. Beeman et al. (1994) suggested that the right hemisphere may weakly activate large semantic fields, and this may allow people to connect distantly related concepts necessary for making inferences. In addition, a recent fMRI study showed that reading sentences with difficult syntactic structures produced more activation in the right hemisphere than reading sentences with easy syntactic structures (Just et al., 1996).

The bilateral activation in the adults during the sentence task in our study may have resulted for the following reason. For many processes, research has found that increases in automaticity lead to decreases in the size of the brain area needed to control the process (Raichle et al., 1994). When people are trying to comprehend a subject-relative sentence, such as "The dog that chased the cat bit the rat,"

they can use well-learned mechanisms and there is no need for a perspective shift. In the case of the object-relative sentences, such as “The dog that the cat chased bit the rat,” there is a perspective shift from “dog” to “cat” and then back to “dog” (Booth et al., 2000). In the object-relative sentences, participants need to use memory to store the initial subject, then shift attention to the subject of the relative clause and then shift back to the subject of the main clause. Therefore, comprehending these sentences requires perspective taking, memory storage, and a related shift of attention. If the child comprehends the object-relative sentence incorrectly, by using the subject-relative template, no additional demand on processing resources is made. However, if the sentence is comprehended correctly, more brain activation is triggered. Therefore, the bilateral activation in this task in adults may be indicative of their sensitivity to the greater difficulty of the object-relative form. The children tend to show less bilateral activation, largely because they are not processing the object-relative sentences as fully as are the adults.

The second developmental difference was that children showed more activation in the inferior portion of the occipital lobe. The activation of occipital regions in a language task could be explained by differences between children and adults in sentence processing strategies. Children may try to imagine sentence participants and actions in their attempt to comprehend these difficult sentences, whereas adults may rely more on a strictly linguistic strategy. The hypothesis that children rely on visual imagery is consistent with other studies finding increased activation in the extrastriate cortex during visual imagery (see Kosslyn, 1994). The adults may have relied more on linguistic representations when listening to the sentences, so their patterns of activation were primarily confined to temporal and frontal areas.

The third developmental difference was that activation in the prefrontal area was right lateralized in adults but left lateralized in children. Because these sentences are difficult, children may have to concentrate on encoding the verbal material. The more sophisticated verbal abilities of the adults may allow them to effectively encode the verbal material, so they can concentrate on retrieving sentence information during the question. These developmental differences in encoding and retrieval may have produced differences between the children and adults in activation asymmetry in prefrontal areas. Fletcher et al. (1995) showed that encoding in episodic memory is associated with activation in the left prefrontal cortex, whereas retrieval from episodic memory is associated with activation in the right prefrontal cortex. An alternative hypothesis is that more activity in the right prefrontal for adults may reflect decisional processes associated with inferential processing, as studies show that adults with right hemisphere lesions tend to have inferential deficits (Brownell, Potter, Bihrlé, & Gardner, 1986). Nevertheless, future studies could more directly test the hypothesis of developmental differences in encoding and retrieval by using a single trial imaging approach to examine activation patterns during the encoding of sentences and during the retrieval of the information about sentences.

Sentence Type and Strategy Differences in Sentence Processing

Research has shown that, as the reading task becomes more difficult, there is more activation in bilateral superior temporal and inferior frontal regions (Just et al., 1996). We replicated the finding of greater activation during difficult sentences in our adult population in a listening rather than a reading paradigm. However, the healthy children and pediatric patients in our study did not show robust sentence type differences in their accuracy levels or patterns of brain activation. The lack of sentence type differences for these populations may be because all sentences were rather difficult for them to comprehend.

The exquisite sensitivity of fMRI at the individual level allowed us to examine strategic differences in sentence processing for the healthy children and pediatric patients (Booth et al., 2000). We found that participants who comprehended sentences at chance levels showed little activation in inferior frontal and superior temporal regions, suggesting that they were not fully utilizing their linguistic comprehension network. However, participants who answered questions consistently, regardless of whether they answered them correctly, showed similar degrees of activation in inferior frontal and superior temporal regions, suggesting that they were fully engaging their language network. In fact, participants who answered questions consistently but incorrectly showed the greatest amount of activation in these regions, suggesting that they were trying extremely hard to answer the questions correctly.

Developmental Effects in Mental Rotation in Intact Populations

The mental rotation task activated a neurocognitive network involving regions of the occipital lobe (superior and inferior), inferior temporal, superior parietal, supramarginal gyrus, and middle frontal. These results are consistent with another imaging study that used essentially the same experimental paradigm in adults (Alivisatos & Petrides, 1997).

The activation of the inferior occipital and inferior temporal areas may reflect the participant's activation of the "what" pathway for the recognition of alphanumeric stimuli (Ungerleider & Haxby, 1994). The activation of parietal regions during mental rotation is consistent with other studies that have found that these regions are involved in visual-spatial manipulation (Carpenter et al., 1999; Cohen et al., 1996; Tagaris et al., 1997). Our study showed activation in two distinct regions of the parietal cortex—superior posterior parietal area (BA 7) and supramarginal gyrus (BA 40). Studies on rhesus monkeys showed that there are projections between these two areas (Pandya & Seltzer, 1982). An imaging study

showed that visual localization produces activity in the superior parietal, but not in the inferior parietal cortex (Haxby et al., 1991). It may be that the inferior parietal regions are involved in the recognition of noncanonical views of stimuli, whereas superior parietal regions are more involved in the actual rotation of stimuli (Alivisatos & Petrides, 1997).

One of the striking findings of the mental rotation task was the extent of bilateral activation. This is in contrast to extensive clinical literature, which shows right hemisphere damage disrupts visual-spatial processing. However, mental rotation tasks have not been shown to be related to consistent laterality effects in neurological populations (Newcombe & Ratcliff, 1989), and imaging studies have shown bilateral involvement in mental rotation (Alivisatos & Petrides, 1997; Cohen et al., 1996). Carpenter et al. (1999) suggested that the right parietal area may be more involved in processes that require fast configural judgments and less coordination over time. This is supported by the finding that the 0° angular disparity condition produced more activation in the right hemisphere, whereas the more difficult conditions with greater angular disparity created more symmetrical patterns of activation.

Children and adults activated a similar neurocognitive network for mental rotation; however, there were interesting developmental differences in the distribution of activity in the network. Children showed less activation in the middle frontal and superior parietal regions and more activation in the supramarginal gyrus. This may mean that the adults were successful at mentally rotating the alphanumeric stimuli in the superior parietal lobule with the assistance of executive control from the middle frontal region. Other studies of more complex mental rotation tasks in adults have also shown activation in frontal areas (Cohen et al., 1996; Carpenter et al., 1999), and these findings have implicated spatial working memory systems (Jonides et al., 1993). Children may be showing more activation in the supramarginal gyrus because of their greater difficulty in processing noncanonical forms of stimuli like the backward letters and numbers in our mental rotation task (Alivisatos & Petrides, 1997). The finding of less activation in children in the superior parietal region is consistent with the Tagaris et al. (1997) finding that percentage error was associated with a greater intensity of activation in the left and right superior parietal lobule. It is also consistent with the Carpenter et al. finding that area of activation was associated with the difficulty of the mental rotation task. Taken together, these findings suggest that the superior parietal area is directly involved in the rotation of visual stimuli.

Impact of Pediatric Brain Lesions on Patterns of Activation

In general, our results showed that a lesion to the left hemisphere was associated with organization to homologous areas in the contralateral hemisphere for sentence comprehension and mental rotation; however, there was also activation in the intact

areas of the damaged hemisphere for all pediatric patients. The development of cognitive processing in the intact hemisphere seemed to be more pronounced in children with larger lesions. For example, SJ had the largest lesion to the left hemisphere and his information processing networks activated by the sentence comprehension task were primarily restricted to the intact right hemisphere. The language task produced little activation in the remaining areas of the injured left hemisphere, even though there was available neural tissue. On the other hand, MK had a smaller lesion to the left hemisphere and she exhibited a large amount of bilateral activation in inferior temporal and occipital areas during the sentence comprehension task. To a lesser degree, the healthy children, but not the adults, also activated the occipital area when processing language.

The bilateral organization in children and adults may explain why children with early unilateral lesions are not dramatically impaired in language processing (Bates et al., 1997). These results are consistent with animal studies that show unilateral damage is associated with homologous organization and with small deficits in behavioral performance (Webster et al., 1995). Such studies also show that early bilateral lesions are associated with the recruitment of other brain areas typically involved in different cognitive processes (Webster et al., 1995). None of our pediatric patients had bilateral lesions, so this may explain the minimal amount of recruitment of nontypical brain areas during our cognitive tasks.

CONCLUSION

The distribution of activity in the large-scale neurocognitive networks for sentence comprehension and mental rotation in healthy and injured children was similar to that in healthy adults. However, the distribution of activity across this network varied as a function of age, difficulty of cognitive task, application of strategies, and whether the brain was intact.

ACKNOWLEDGMENTS

This research was funded in part by Grant 5-F32-HD08255-02 from the National Institute of Child Health and Human Development, by Grant 5-R01-HD23998 from the National Institute of Deafness and Communication Disorders, and by Grant 1 PO 1NS35949-01A1 from the National Institute of Neurological Disorders and Stroke.

We thank Yasuaki Harasaki and Frank Van Santen for helpful comments on earlier versions of this manuscript. We thank Claudine Martin for assistance in statistical analyses.

REFERENCES

- Adams, M. J., & Huggins, A. W. F. (1985). The growth of children's sight word vocabulary: A quick test with educational and theoretical implications. *Reading Research Quarterly*, *20*, 560-568.
- Alivisatos, B., & Petrides, M. (1997). Functional activation of the human brain during mental rotation. *Neuropsychologia*, *35*, 111-118.
- Aram, D. M., & Eisele, J. A. (1994). Intellectual stability in children with unilateral brain lesions. *Neuropsychologia*, *32*, 85-95.
- Bates, E., Thal, D., Trauner, D., Fenson, J., Aram, D., Eisele, J., & Nass, R. (1997). From first words to grammar in children with focal brain injury. *Developmental Neuropsychology*, *13*, 275-343.
- Bavelier, D., Corina, D., Jezzard, P., Padmanabhan, S., Clark, V. P., Karni, A., Prinster, A., Lalwani, A., Rauschecker, J. P., Turner, R., & Neville, H. (1997). Sentence reading: A functional MRI study at 4 Tesla. *Journal of Cognitive Neuroscience*, *9*, 664-686.
- Beeman, M., Friedman, R. B., Grafman, J., Perez, E., Diamond, S., & Lindsay, M. B. (1994). Summation priming and coarse semantic coding in the right hemisphere. *Journal of Cognitive Neuroscience*, *6*, 26-45.
- Binder, J. R., Frost, J. A., Hammeke, T. A., Cox, R. W., Rao, S. M., & Prieto, T. (1997). Human brain language areas identified in functional magnetic resonance imaging. *Journal of Neuroscience*, *17*, 353-362.
- Bjorn, K., Madden, R., & Gerdner, E. F. (1984). *Stanford Diagnostic Reading Test* (3rd ed.). New York: Harcourt Brace.
- Booth, J. R., MacWhinney, B., & Harasaki, Y. (2000). Developmental differences in visual & auditory processing of complex sentences. *Child Development*, *71*, 979-1001.
- Braver, T. S., Cohen, J. S., Nystrom, L. E., Jonides, J., Smith, E. E., & Noll, D. (1997). A parametric study of prefrontal cortex involvement in human working memory. *Neuroimage*, *5*, 49-62.
- Brownell, H. H., Potter, H. H., Bihrl, A. M., & Gardner, H. (1986). Inference deficits in right hemisphere damaged patients. *Brain and Language*, *29*, 310-321.
- Carpenter, P. A., Just, M. A., Keller, T. A., Eddy, W., & Thulborn, K. (1999). Graded functional activation in the visuo-spatial system with the amount of task demand. *Journal of Cognitive Neuroscience*, *11*, 9-24.
- Carter C. S., Braver T. S., Barch D. M., Botvinick M. M., Noll D. C., & Cohen J. D. (1998). Anterior cingulate cortex, error detection and the on-line monitoring of performance. *Science*, *280*, 747-749.
- Chugani, H. T., Phelps, M. E., & Mazziotta, J. C. (1987). Positron emission tomography of human brain functional development. *Annals of Neurology*, *22*, 487-497.
- Cohen, J. D., MacWhinney, B., Flatt, M., & Provost, J. (1993). PsyScope: An interactive graphic system for designing and controlling experiments in the psychology laboratory using Macintosh computers. *Behavior Research Methods, Instruments, and Computers*, *25*, 257-271.
- Cohen, M. S., Kosslyn, S. M., Breiter, H. C., DiGirolamo, G. J., Thompson, W. L., Anderson, A. K., Bookheimer, S. Y., Rosen, B. R., & Belliveau, J. W. (1996). Changes in cortical activity during mental rotation: A mapping study using functional MRI. *Brain*, *119*, 89-100.
- Cox, R. W. (1996). AFNI: Software for analysis and visualization of functional magnetic resonance neuroimages. *Computers and Biomedical Research*, *29*, 162-173.
- Demonet, J. F., Chellet, R., Ramsay, S., Cardebat, D., Nespoulous, J. L., Wise, R., Rascol, A., & Frackowiak, R. (1992). The anatomy of phonological and semantic processing in normal subjects. *Brain*, *115*, 1753-1768.
- Dronkers, N. F., Redbern, B. B., & Ludy, C. A. (1995). Lesion localization in chronic Wernicke's aphasia. *Brain and Language*, *51*, 62-65.
- Dunn, L., & Dunn, L. (1981). *Peabody Picture Vocabulary Test Revised*. Circle Pines, MN: American Guidance Service.

- Eddy, W. F., Fitzgerald, M., Genovese, C. R., Mockus, A., & Noll, D. C. (1997). Functional imaging analysis software—computational olo. In A. Pratt (Ed.), *Proceedings in computational statistics* (pp. 39–49). Heidelberg, Germany: Physica-Verlag.
- Engelien, A., Silbersweig, D., Stern, E., Huber, W., Doring, W., Frith, C., & Frackowiak, R. S. J. (1995). The functional anatomy of recovery from auditory agnosia. *Brain*, *118*, 1395–1409.
- Finger, S. (1991). Brain damage, development, and behavior: Early findings. *Developmental Neuropsychology*, *7*, 261–274.
- Fletcher, P. C., Frith, C. D., Grasby, P. M., Shallice, T., Frackowiak, R. S. J., & Dolan, R. J. (1995). Brain systems for encoding and retrieval of auditory–verbal memory: An in vivo study in humans. *Brain*, *118*, 401–416.
- Frith, C. D., Friston, K. J., Liddle, P. F., & Frackowiak, R. S. (1991). A PET study of word finding. *Neuropsychologia*, *29*, 1137–1148.
- Hart, K. J., & Faust, D. (1988). Prediction of the effects of mild head injury: A message about the Kennard Principle. *Journal of Clinical Psychology*, *44*, 780–782.
- Haxby, J. V., Grady, C. L., Horowitz, B., Ungerleider, L. G., Mishkin, M., Carson, R. E., Herschovitch, P., Schapiro, M. B., & Rapaport, S. I. (1991). Dissociation of object and spatial visual processing pathways in the human extrastriate cortex. *Proceedings of the National Academy of Sciences, USA*, *88*, 1621–1625.
- Hayden Image Processing Group. (1997). *Alice*. Boulder, CO: Perceptive Systems, Inc.
- Howard, D., Patterson, K., Wise, R., Brown, W. D., Friston, K., Weiller, C., & Frackowiak, R. (1992). The cortical localization of the lexicons: Positron emission tomography evidence. *Brain*, *115*, 1769–1782.
- Huttenlocher, P. R. (1990). Morphometric study of human cerebral cortex development. *Neuropsychologia*, *28*, 517–527.
- Jonides, J., Schumacher, E. H., Smith, E. E., Lauber, E., Awh, E., Minoshima, S., & Koeppel, R. A. (1997). Verbal working memory load affects regional brain activation as measured by PET. *Journal of Cognitive Neuroscience*, *9*, 462–475.
- Jonides, J., Smith, E. E., Koeppel, R. A., Awh, E., Minoshima, S., & Mintun, M. A. (1993). Spatial working memory in humans as revealed by PET. *Nature*, *363*, 623–625.
- Just, M. A., Carpenter, P. A., Keller, T. A., Eddy, W. F., & Thulborn, K. R. (1996). Brain activation modulated by sentence comprehension. *Science*, *274*, 114–116.
- Kaas, J. H. (1995). The reorganization of sensory and motor maps in adult mammals. In M. Gazzaniga (Ed.), *The cognitive neurosciences* (pp. 51–71). Cambridge, MA: MIT Press.
- King, J., & Just, M. A. (1991). Individual differences in syntactic processing: The role of working memory. *Journal of Memory and Language*, *30*, 580–602.
- Kinsbourne, M., & Hiscock, M. (1987). Language lateralization and disordered language development. In S. Rosenberg (Ed.), *Advances in applied psycholinguistics* (pp. 220–263). New York: Cambridge University Press.
- Kolb, B., & Gibb, R. (1991). Sparing of function after neonatal frontal lesions correlates with increased cortical dendritic branching: A possible mechanism for the Kennard effect. *Behavioural Brain Research*, *43*, 51–56.
- Kosslyn, S. M. (1994). *Image and brain*. Cambridge, MA: MIT Press.
- Kosslyn, S. M., & Koenig, O. (1992). *Wet mind: The new cognitive neuroscience*. New York: Free Press.
- Lashley, K. S. (1933). Interactive functions in the cerebral cortex. *Psychological Review*, *13*, 1–42.
- Leiter, R. G. (1980). *Leiter International Performance Scale*. Wood Dale, IL: Stoelting Co.
- Lenneberg, E. H. (1967). *Biological foundations of language*. New York: Wiley.
- Mazoyer, B. M., Tzourio, N., Frak, V., Syrota, A., Murayama, N., Levrier, O., Salamon, G., Dehaene, S., Cohen, L., & Mehler, J. (1993). The cortical representation of speech. *Journal of Neuroscience*, *5*, 467–479.

- Mesulam, M. M. (1998). From sensation to cognition. *Brain*, *121*, 1013–1052.
- Mishkin, M., Ungerleider, L. G., & Macko, K. A. (1983). Object and spatial vision: Two cortical pathways. *Trends in Neuroscience*, *6*, 414–417.
- Muller, R. A., Rothermel, R. D., Behen, M. E., Muzik, O., Mangner, T. J., Chakraborty, P. K., & Chugani, H. T. (1998). Brain organization of language after early unilateral lesion: A PET study. *Brain and Language*, *62*, 422–451.
- Muller, R. A., Rothermel, R. D., Behen, M. E., Muzik, O., Mangner, T. J., & Chugani, H. T. (1998). Differential patterns of language and motor reorganization following early left hemisphere lesion. *Archives of Neurology*, *55*, 1113–1119.
- Muter, V., Taylor, S., & Vargha-Khadem, F. (1997). A longitudinal study of early intellectual development in hemiplegic children. *Neuropsychologia*, *35*, 289–299.
- Newcombe, F., & Ratcliff, G. (1989). Disorders of visuo-spatial analysis. In F. Boller & J. Grafman (Eds.), *Handbook of neuropsychology* (pp. 333–356). Amsterdam: Elsevier.
- Ojemann, G. A. (1991). Cortical organization of language. *The Journal of Neuroscience*, *11*, 2281–2287.
- Olfield, R. C. (1971). The assessment and analysis of handedness: The Edinburgh inventory. *Neuropsychologia*, *9*, 97–113.
- Olson, R. K., Kliegl, R., Davidson, B. J., & Foltz, G. (1985). Individual and developmental differences in reading disability. In G. E. MacKinnon & T. G. Waller (Eds.), *Reading research: Advances in theory and practice* (pp. 1–64). Orlando, FL: Academic.
- Pandya, D. N., & Seltzer, B. (1982). Intrinsic connections and architectonics of the posterior parietal cortex in the rhesus monkey. *Journal of Comparative Neurology*, *204*, 196–210.
- Papanicolaou, A. C., Discenna, A., Gillespie, L., & Aram, D. (1990). Probe-evoked potential findings following unilateral left-hemisphere lesions in children. *Archives of Neurology*, *47*, 562–566.
- Petersen, S. E., & Fiez, J. A. (1993). The processing of single words studied with positron emission tomography. *Annual Review of Neuroscience*, *16*, 509–530.
- Poeppel, D. (1996). A critical review of PET studies of phonological processing. *Brain and Language*, *55*, 317–351.
- Raichle, M. E., Fiez, J. A., Videen, T. O., MacLeod, A. K., Pardo, J. V., Fox, P. T., & Petersen, S. E. (1994). Practice-related changes in human brain functional anatomy during non-motor learning. *Cerebral Cortex*, *4*, 8–26.
- Ramachandran, V. S. (1993). Behavioral and magnetoencephalographic correlates of plasticity in the adult human brain. *Proceedings of the National Academy of Sciences, USA*, *90*, 10413–10420.
- Rosenberg, D. R., Sweeney, J. A., Gillen, J. S., Chang, S. Y., Varanelli, M. J., O'Hearn, K., Erb, P. A., Davis, D., & Thulborn, K. R. (1997). Magnetic resonance imaging of children without sedation: Preparation with simulation. *Journal of the American Academy of Child Adolescent Psychiatry*, *36*, 853–859.
- Schneider, G. E. (1979). Is it really better to have your brain lesion early? A revision of the "Kennard principle." *Neuropsychologia*, *17*, 557–583.
- Semel, E., Wiig, E., & Secord, W. (1989). *The clinical evaluation of language function—revised*. San Antonio, TX: Psychological Corporation.
- Shepard, R. N., & Metzler, J. N. (1971). Mental rotation of three-dimensional objects. *Science*, *171*, 701–703.
- Steinmetz, H., & Seitz, R. J. (1991). Functional anatomy of language processing: Neuroimaging and the problem of individual variability. *Neuropsychologia*, *29*, 1149–1161.
- Stiles, J., Trauner, D., Engel, M., & Nass, R. (1997). The development of drawing in children with congenital focal brain injury: Evidence for the limited functional recovery. *Neuropsychologia*, *35*, 299–312.

- Sundsten, J. W. (1994). *Digital anatomist: Interactive brain atlas*. Seattle: University of Washington, Health Sciences Center for Educational Resources.
- Tagaris, G. A., Kim, S. G., Strupp, J. P., Andersen, P., Ugurbil, K., & Georgopoulos, A. P. (1997). Mental rotation by functional magnetic resonance imaging at high field (4 Tesla): Performance and cortical activation. *Journal of Cognitive Neuroscience*, *9*, 419–432.
- Talairach, J., & Tournoux, P. (1988). *Co-planar stereotaxic atlas of the human brain*. New York: Georg Thieme Verlag Stuttgart.
- Teuber, H. L., & Rudel, R. G. (1962). Behavior after cerebral lesions in children and adults. *Developmental Medicine and Child Neurology*, *4*, 3–20.
- Thulborn, K. R., Davis, D., Erb, P., Strojwas, M., & Sweeney, J. A. (1996). Clinical fMRI: Implementation and experience. *NeuroImage*, *4*, S101–S107.
- Tootell, R. B. H., Reppas, J. B., Kwong, K. K., Malach, R., Born, R. T., Brady, T. J., Rosen, B. R., & Belliveau, J. W. (1995). Functional analysis of human MT and related visual cortex areas using magnetic resonance imaging. *The Journal of Neuroscience*, *15*, 3215–3230.
- Ungerleider, L. G., & Haxby, J. V. (1994). “What” and “where” in the human brain. *Current Opinion in Neurobiology*, *4*, 157–165.
- Van Kleek, M. H. (1989). Hemispheric differences in global versus local processing of hierarchical visual stimuli by normal subjects: New data and meta-analysis. *Neuropsychologia*, *27*, 1165–1178.
- Vorob'ev, V. A., Korotkov, A. D., Pakhomov, S. V., Rozhdestvenskii, D. G., Rudas, M. S., Bekhtereva, N. P., & Medvedev, S. V. (1998). Brain mechanisms for the processing of visually presented verbal stimuli at different levels of their integration: II. Orthographic and syntactic aspects. *Human Physiology*, *24*, 435–443.
- Voyvodic, J. (1999). Real-time fMRI paradigm control, physiology, and behavior combined with near real-time statistical analysis. *Neuroimage*, *10*, 91–106.
- Webster, M. J., Bachevalier, J., & Ungerleider, L. G. (1995). Development and plasticity of visual memory circuits. In B. Julesz & I. Kovacs (Eds.), *Maturational windows and adult cortical plasticity* (pp. 73–86). New York: Addison-Wesley.
- Weiller, C., Isensee, C., Rijntjes, M., Huber, W., Muller, S., Bier, D., Dutschka, K., Woods, R. P., & Diener, H. C. (1995). Recovery from Wernicke's aphasia: A positron emission tomographic study. *Annals of Neurology*, *37*, 723–732.
- Whishaw, I. Q., & Kolb, B. (1988). Sparing of skilled forelimb reaching and corticospinal projections after neonatal motor cortex removal or hemidecortication in the rat: Support for the Kennard doctrine. *Brain Research*, *451*(1–2), 97–114.
- Woodcock, R. W. (1987). *Woodcock Reading Mastery Tests—Revised*. Circle Pines, MN: American Guidance Service.
- Zurif, E., & Swinney, D. (1994). The neuropsychology of language. In M. A. Gernsbacher (Ed.), *Handbook of psycholinguistics* (pp. 1055–1074). New York: Academic.