



PII S0278-5846(99)00025-1

FUNCTIONAL ORGANIZATION OF ACTIVATION PATTERNS IN CHILDREN: WHOLE BRAIN fMRI IMAGING DURING THREE DIFFERENT COGNITIVE TASKS

JAMES R. BOOTH¹, BRIAN MACWHINNEY², KEITH R. THULBORN³,
KELLEY SACCO⁴, JAMES VOYVODIC³ and HEIDI M. FELDMAN¹

¹Department of Communication Sciences and Disorders,
Northwestern University, Evanston, IL, USA

²Department of Psychology, Carnegie Mellon University, Pittsburgh, PA, USA

³Department of Radiology, University of Pittsburgh, Pittsburgh, PA, USA
and ⁴Department of Pediatrics, University of Pittsburgh School of Medicine,
Children's Hospital of Pittsburgh, Pittsburgh, PA, USA.

(Final form, February 1999)

Abstract

Booth, James R., Brian Macwhinney, Keith R. Thulbom, Kelley Sacco, James Voyvodic, and Heidi M. Feldman. Functional Organization of Activation Patterns in Children: Whole Brain fMRI Imaging During Three Different Cognitive Tasks. *Progress in Neuro-Psychopharmacol & Biol. Psychiat.* 1999, 23, pp. 669-682. © 1999 Elsevier Science Inc.

1. Patterns of brain activation were measured with whole brain echo-planar functional magnetic resonance imaging (fMRI) at 3.0 Tesla in healthy children ($N=6$) and in one child with a left-hemisphere encephalomalacic lesion as sequellae from early stroke.
2. Three cognitive tasks were used: auditory sentence comprehension, verb generation to line drawings, and mental rotation of alphanumeric stimuli.
3. There was evidence for significant bilateral activation in all three cognitive tasks for the healthy children. Their patterns of activation were consistent with previous functional imaging studies with adults.
4. The child with a left-hemisphere stroke showed evidence of homologous organization in the non-damaged hemisphere.

Keywords: cognitive processing, functional magnetic resonance imaging, pediatric, stroke

Abbreviations: magnetic resonance imaging (MRI)

Introduction

For centuries, scientists have wondered and researchers have attempted to understand exactly how the human brain organizes to recover function after injury. Studies have attempted to understand the degree to which multiple brain areas are equipotential and can compensate for each other after injury or are intrinsically specialized and thus limited in their ability to compensate for lost function (Kaas, 1995;

Kinsbourne and Hiscock, 1983; Kosslyn and Koenig, 1992; Lashley, 1933; Lenneberg, 1967; Van Kleek, 1989; Webster *et al.*, 1995).

Behavioral research on children with focal brain lesions has shown that language functions are preserved relative to spatial functions (Aram and Eisele, 1994; Bates *et al.*, 1997; Mimer, 1973; Muter *et al.*, 1997; Stiles *et al.*, 1997; Teuber and Reudel, 1962). One possible explanation for these behavioral effects is that, after injury to a hemisphere, language functions organize to homologous areas in the contralateral hemisphere, and thus compromise functions normally performed in that hemisphere (Papanicolaou *et al.*, 1990). The hypothesis that language functions served by damaged areas to the superior temporal and inferior frontal gyri organize to contralateral homologous areas is plausible for several reasons. First, the superior temporal areas in both the right and left hemispheres are specialized for processing auditory information (Heffner and Heffner, 1984). Second, adult stroke patients undergo a period of recovery that leads to increased activation bilaterally during auditory and language tasks (Engelien *et al.*, 1995; Weiller *et al.*, 1995). Third, fMRI studies with normal adults show that increasing cognitive task difficulty increases the magnitude of bilateral activation in homologous areas as well as the intensity and volume of the neural response within a hemisphere (Braver *et al.*, 1997; Just *et al.*, 1996). However, a lesion also reduces the total amount of neural tissue, so it is possible that non-homologous adjacent brain areas may be increasingly activated during cognitive operations (Ramachandran, 1993). Thus, previous literature suggests that after injury there should be organization to contralateral homologous brain areas as well as local organization to ipsilateral adjacent areas. In this study, fMRI techniques were used to examine the functional organization of cognitive processing in healthy children and in a child with a left-hemisphere stroke in order to shed light on these long-standing issues of plasticity and localization.

Three experimental tasks were designed to investigate the functional organization of large scale neural networks involved in language, executive semantic search, and visual-spatial manipulation. We chose three experimental tasks that had been successfully employed in adult studies of brain activation. None of these tasks have been used to examine brain activation in children. The first language task, auditory sentence comprehension, was expected to produce activation in superior temporal and inferior frontal areas (Binder *et al.*, 1997; Just *et al.*, 1996). The second executive semantic search task, verb generation to line drawings, was expected to produce activation in inferior temporal and inferior frontal regions (Kapur *et al.*, 1994; Petersen *et al.*, 1988; Ungerleider and Haxby, 1994; Warburton *et al.*, 1996). The third visual-spatial manipulation task, mental rotation of alphanumeric stimuli, was expected to produce activation in parietal areas (Alivisatos and Petrides, 1997).

Methods

Subjects

The participants in this study were six healthy right-handed children (9 to 12 years old, 4 boys and 2 girls) and one child with a left-hemisphere stroke. All children were native English speakers. Informed consent was obtained from all subjects with an experimental protocol approved by the University of Pittsburgh Institutional Review Board.

The child with the stroke (SJ) was left-handed as the result of a right-sided hemiparesis related to his left-sided cortical injury. SJ was a 12-year-old boy who suffered a large middle cerebral artery stroke at one month of age during cardiac catheterization. Volumetric analysis of the structural magnetic resonance image (MRI) scans revealed that SJ's left hemisphere cortex was 56% smaller than his right. The following brain areas were preserved in SJ: medial-posterior occipital lobe, posterior-inferior temporal gyms, posterior occipital-temporal gyrus, medial orbital gyrus, medial frontal pole, anterior-superior frontal gyrus, and anterior middle frontal **gyrus**. SJ was also given a battery of standardized cognitive tests. SJ had normal non-verbal intelligence on the Leiter International Performance Scale (Leiter, 1980) and normal receptive vocabulary scores on the Peabody Picture Vocabulary Test (PPVT-R, Dunn and Dunn, 1981). However, SJ had deficits in formulating sentences and recalling sentences on the Clinical Evaluation of Language Function (CELF-R, Semel et al, 1989). In addition, SJ had deficits in short-term memory as measured by an auditory digit span (Daneman and Merikle, 1996) and severe deficits in word recognition skills on the Word Identification and Word Attack tests (Woodcock, 1987).

Cognitive Tasks

The present sentence comprehension task was based on other studies performed in our lab (Booth and MacWhinney, under review) with 250 elementary students. Each sentence was presented continuously over the earphones. There were three sentence types that ranged in complexity from harder object relative sentences, such as "The pig that the dog jumped ate the trash in the street", to moderate subject relative sentences, such as "The principal that tripped the janitor used the phone to call home", to easier conjoined verb phrase sentences, such as "The cat chased the rabbit and enjoyed the hunt in the yard". After listening to each sentence, the subject was asked to answer a true-false question by pressing the appropriate button on a button box. The question either tested for the subject of the first verb, e.g. "The dog jumped the pig?", or the subject for the second verb, e.g. "The principal used the phone?". During each trial, the subject heard a 1000 ms warning signal (i.e., "listen") followed by a sentence presented during a 6500 ms interval, and then they heard a 1000 ms warning signal (i.e., "question") followed by a question presented during a 6500 ms interval. Each of the 9 experimental blocks (60 s each) contained 4

sentences of the same type (3 blocks for each sentence type) and **these** were interleaved **with 9** rest blocks consisting of a visual fixation cross (40 s each).

In the verb generation task, subjects were asked to view a line drawing of an object (Snodgrass and Vanderwart, 1980) and to silently generate actions that they could perform on that object. For example, if the line drawing was a picture of a banana, they could silently generate “eat”, “peel”, and “slice”. Each of the 5 experimental blocks (80 s each) contained 16 pictures presented for 5 s each and these were interleaved with 5 rest blocks consisting of a visual fixation cross (40 s each). No response was measured in this task - although subjects reported being able to generate one or more actions for each object.

In the mental rotation task, subjects were asked to mentally rotate a letter or number (2, 5, 7, G, F, R) to its upright position and to determine, after rotating, whether the letter or number was forward or backward (Alivisatos and Petrides, 1997). The subject was asked to press the appropriate button on the button box to indicate if the stimulus was forward or backward. Each of the 6 experimental blocks (72 s each) contained 24 stimuli presented for 3 s each and these were interleaved with 6 rest blocks consisting of a visual fixation cross (40 s each). The stimuli were presented at 4 different orientations (0°, 135°, 180°, and 225° from upright).

MRI Procedure

Before the fMRI procedure, all subjects participated in a 1 hour practice session which involved practicing the three cognitive tasks. Before the scan, the children were also acclimated to the scanner environment in a simulator (Rosenberg et al, 1997).

All images were acquired using a 3.0-T GE Medical Systems scanner with a head coil at the Magnetic Resonance Research Center of the University of Pittsburgh Medical Center. Gradient echo-planar fMRI with BOLD (blood oxygenation level-dependent) was used for all functional scans. Functional images were acquired at a repetition time (TR) of 4500ms in 21 axial or oblique axial slices. Other functional scan parameters were: time of echo (TE) = 25ms; flip = 90°; field of view = 400x200mm; slice thickness = 3mm, slice gap = 1mm; acquisition matrix = 128x64; voxel size = 3x3x3mm. High resolution T1-weighted spin echo structural scans (axial SPGR) were acquired for anatomical localization. Structural scan parameters were: TR = 25ms; TE = 4ms, flip = 40°; acquisition matrix = 256x256, # slices = 124; field of view = 240x180mm.

Data Analysis

Image movement for the functional scans was determined by FIASCO (Eddy et al, 1997). If there was excessive movement during part of the scan, that section was removed from the functional analyses with the stipulation that no more than one block from each cognitive task be removed. After this procedure, 11 out of 18 paradigms for the healthy children (6 children in 3 cognitive tasks) exhibited acceptable levels of motion. All paradigms had at least 3 useable data sets for the healthy children. For the useable data sets, the mean of the maximum head motion across subjects was .12 of a voxel for both SJ and the healthy children. Maximum movement was not more than .25 of a voxel for any of the subjects in any of the paradigms.

A voxel was considered active if a t-test comparing activation in the experimental condition compared to activation in the rest condition was above a threshold value ($t > 5.0$). The same threshold was used for all subjects. To determine the location of each activated voxel, we superimposed the functional activation images onto the high-resolution structural images using AFNI (Cox, 1996). We then calculated the number of activated voxels in each region of interest based on Talairach coordinates (Talairach and Tournoux, 1988).

Results and Discussion

Behavioral Outcomes

As expected for the sentence task (Booth and Macwhinney, under review), the healthy children exhibited slightly lower accuracy levels for the harder object relative sentences than for the moderate subject relative sentences or for the easy conjoined verb sentences. SJ was scoring at comparable levels to the healthy children on the harder and moderate sentence types. SJ even scored at higher levels than the healthy children on the easy sentence type (Table 1).

As expected for the mental rotation task (Shepard and Metzler, 1971), the healthy children exhibited higher accuracy levels for the easy 0° condition and lower accuracy levels for the hard 180° condition. Accuracy levels were in the middle for the 135° and 225° conditions. The percentages correct for SJ were substantially lower than the healthy children for more difficult orientations (Table 1). However, SJ scored at similar levels to the healthy children on the easiest orientation suggesting that he was cognitively engaged in the task.

SJ's superior performance on the sentence comprehension task relative to the mental rotation task supports other studies that have found preserved language functioning relative to visual-spatial

functioning (Aram and Eisele, 1994; Bates et al., 1997; Milner, 1973; Muter et al, 1997; Stiles et al, 1997).

Table 1

Percentage Correct (%) on the Sentence Comprehension and Mental Rotation Tasks for Healthy Children ($N=6$) and for the Child with a Left Hemisphere Stroke (SJ).

	Child	SJ
Sentence Comprehension		
Easy	68	83
Moderate	66	58
Difficult	65	58
Mental Rotation		
0°	85	89
135°	73	46
225°	84	47
180°	70	54

Regions of Interest

Our measure of brain activation was the percentage of total voxels activated in nine regions of interest (Fig 1). These regions were the areas of greatest activation in our healthy subjects. They also correspond to areas of activation found in previous imaging studies using similar paradigms (Alivisatos and Petrides, 1997; Binder et al, 1997; Just et al, 1996, Kapur et al, 1994; Petersen et al, 1988; Warburton et al, 1996). The nine regions of interest included three frontal areas (superior, pre, inferior), two temporal areas (superior, inferior), two parietal areas (inferior, superior), an occipital area, and a cingulate area.

Figure 2 displays the mean percentage of voxels activated in the nine regions of interest for the healthy children and individual results for the child with a left hemisphere stroke (SJ). The brain activation data are presented separately for the 3 different experimental paradigms and for the right versus left hemispheres. Figure 3 presents the functional images superimposed on the high-resolution structural images. The mean number of voxels activated across all regions of interest were 2 18,607, and 146 for the healthy children for the sentence comprehension, verb generation, and mental rotation tasks, respectively. The corresponding numbers were 164, 451, and 49 for SJ.

For the healthy children, an analysis of variance (ANOVA) on percentage of activated voxels with hemisphere (right, left), region of interest (9 regions), and paradigm (sentences, verbs, rotation) as

independent variables showed a significant interaction between region of interest and paradigm, $F(16, 594) = 3.81, p < .001$.

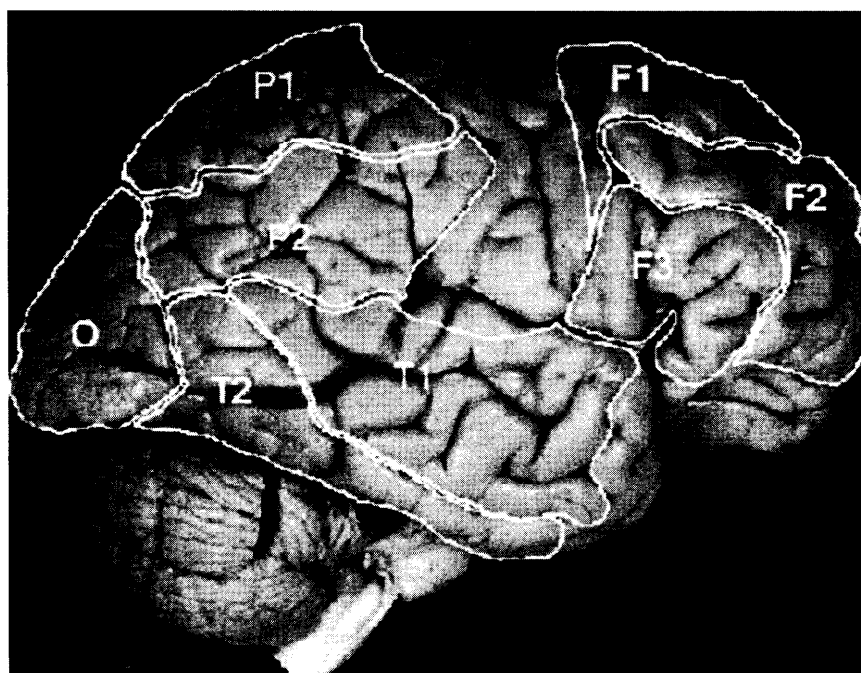


Fig 1. Nine regions of interest (Brodmann's areas in parentheses): F1- superior frontal (6, 8); F2 - prefrontal (9, 10); F3 - inferior frontal (44, 45, 46, 47); T1 - superior temporal (21, 22); T2 - inferior temporal (20, 37); O - occipital (17, 18, 19); P1- inferior parietal (39, 40); P2 - superior parietal (7); C - cingulate (30, 31, 32). The 21 acquisition slices covered most of the brain except for the superior portion of the central sulcus and the inferior portion of the temporal lobe (including inferior portion of Brodmann's Area 20, 36, and 38). The inferior portions of the temporal lobes were not scanned due to image artifacts created by the orbits and nasal cavities (from Sundsten, 1994).

Sentence comprehension produced significant activation in superior temporal and inferior frontal regions. These patterns of activation are broadly consistent with previous studies (Binder et al, 1997; Just et al, 1996). We also found activation in the prefrontal area which suggests that the sentence processing task placed demands on working memory (Braver et al, 1997). Finally, we found activation in the occipital regions. It appears that children are using brain regions not typically activated in adults when involved in this difficult sentence task. Children may use imagery strategies when trying to comprehend these difficult sentences and this may produce the activation in the extrastriate area (Kosslyn, 1994).

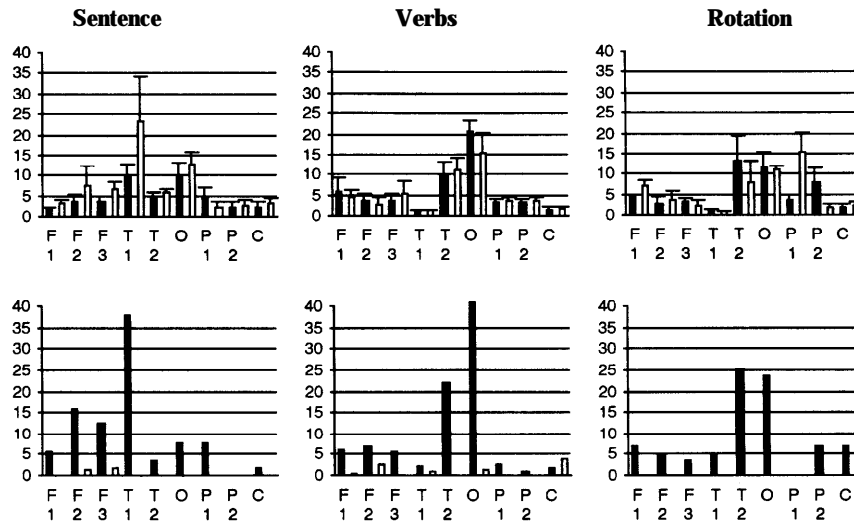


Fig 2. Percentage of total voxels activated in each region of interest for the three cognitive paradigms. Data in first row represent healthy children ($N=6$). Data in second row represent child with stroke (SJ). Black bars represent right hemisphere and open bars represent left hemisphere. Regions of interest are represented on the x-axis. Error bars indicate one standard error for the healthy children.

Verb generation produced significant activation in inferior temporal and occipital regions. These results are consistent with studies that show that these regions are activated in tasks that involve object recognition (Ungerleider and Haxby, 1994). There was, however, little activity in the prefrontal area during our verb generation task. This is in contrast to categorization and verb generation studies of written words (Kapur et al, 1994; Petersen et al, 1988; Warburton et al, 1996). We may have not found much activation in prefrontal areas because our verb generation task involved object, rather than word, recognition. The generation of verbs to objects may involve imagery processes because of the associated visual processing and this may have produced activation in the extrastriate area (Kosslyn, 1994).

Mental rotation produced significant activation in inferior and superior parietal regions. These patterns of activation are broadly consistent with previous studies and suggest that parietal areas are involved in visual spatial manipulation (Alivisatos and Petrides, 1997). We also found activation in the occipital and inferior temporal areas. This may reflect the participant's recognition of the alphanumeric stimuli.

Left versus Right Hemisphere Activation

To determine the relationship between the patterns of activation in the right and left hemispheres, correlations were computed between percentage of voxels activated in each left hemisphere region of

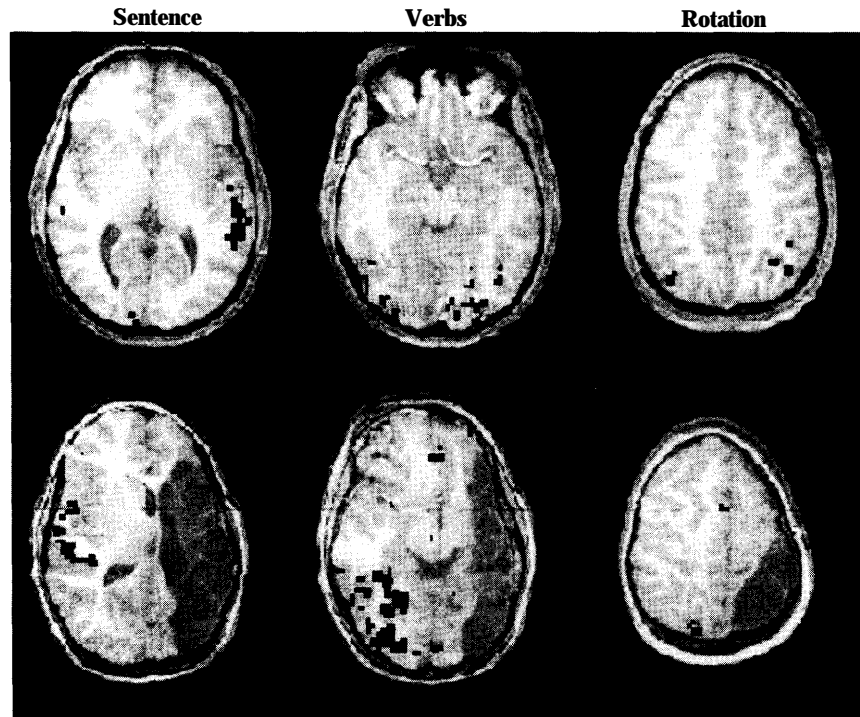


Figure 3. Functional activation superimposed on high-resolution structural images. Black squares indicate significant activation ($t > 5.0$) in the experimental paradigm compared to resting level fixation. Data in first row represent mean for healthy children ($N=6$). Data in second row represent the child with a stroke (SJ). Slice for sentence processing task is through superior temporal gyrus, slice for verb generation task is through visual association area, and slice for mental rotation task is through superior parietal area. The high resolution structural image for the healthy children is from a representative child. Note that the darker gray in the panels for SJ illustrate the extent of his lesion.

interest with the corresponding percentages for the right hemisphere regions of interest. For the healthy children, there were similar patterns of activation in the two hemispheres for sentence comprehension, $r(9)=.86, p<.01$, and for verb generation, $r(9)=.96, p<.001$; but not for mental rotation, $r(9)=.40, ns$. The lower correlation for the mental rotation task resulted from the fact that inferior parietal was more active in the right hemisphere whereas superior parietal was more active in the left hemisphere. The lower correlation between the pattern of activity in the right and left hemisphere for the mental rotation task is consistent with arguments that certain visual-spatial skills may be lateralized in children and adults (Stiles et al, 1997). In general, however, our results suggest that most cognitive processes utilize bilateral brain regions but that one hemisphere may be dominant (Lenneberg, 1967; Kosslyn and Koenig, 1992). Our finding of extensive bilateral activation is in contrast to the widely held belief in rigid lateralization (Kinsbourne and Hiscock, 1983; Van Kleek, 1989). We may have found a large amount of bilateral

activation because of the cognitive difficulty of our tasks (Just et al., 1996) and because of the increased sensitivity of BOLD (blood oxygenation level-dependent) contrast in fMRI at 3.0 Tesla (Thulbom et al., 1996).

Patterns of Brain Activation in Child with Left Hemisphere Stroke

To determine the relationship between patterns of activation in SJ and the healthy children, correlations were computed with percentage of voxels activated in each anatomical region of interest (Table 2). The pattern of activation in SJ's intact right hemisphere was similar to the healthy children's right hemisphere pattern of activation for all cognitive tasks. SJ's information processing networks were primarily restricted to the intact right hemisphere. The cognitive tasks produced little activation in the remaining areas of the injured left hemisphere, except for limited activation in prefrontal and cingulate areas during verb generation. SJ also showed little activation in his intact right hemisphere during mental rotation, especially in the superior parietal region. This may explain his poor performance on this visual-spatial task. In sum, the brain activation patterns for SJ suggest that when one hemisphere is badly damaged, the patterns of activation created in the intact hemisphere are similar to the patterns of activation found in healthy children. However, SJ's limited neural substrate may prevent him from attaining normal levels on standardized language and reading tasks (Teuber and Ruedel, 1962).

Table 2

Correlation between the Mean Pattern of Activation for Healthy Children ($N=6$) and the Pattern of Activation for the Child with a Left Hemisphere Stroke (SJ).

	Sentence		Verbs		Rotation	
	Right ^a	Left	Right	Left	Right	Left
Right	.63 ^b	-.19	.98*	-.17	.90*	---
Left	.88* ^c	-.04	.96*	-.27	.29	---

^aData is broken down into right versus left hemispheres; ^bCorrelations are based on percentage of voxels activated in the nine regions of interest; ^c* indicates $p < .05$

As discussed earlier, Table 1 shows accuracy levels on the sentence comprehension and mental rotation task varied considerably. In a separate investigation, Booth et al (under review) examined the relationship between accuracy on these tasks and amount of activation in different brain regions in a sample of adults and children. This report showed that sentence comprehension accuracy was

positively associated with amount of activation in the middle temporal area and that accuracy was negatively related with amount of activation in the inferior visual association area. The latter finding primarily results because children had lower comprehension accuracy scores and also had greater activation in the inferior occipital area, as compared to adults. For the mental rotation task, the Booth et al (under review) report showed that response accuracy was positively related to amount of activation in the superior parietal region.

Conclusions

The nature and extent of neural plasticity and organization have been debated for decades and only now are we able to provide answers to some of these questions with a non-invasive imaging technology (fMRI). There have only been a few studies examining brain activation patterns in adults after brain injury (Engelien et al, 1995; Weiller et al, 1995). The present research is the first to examine patterns of brain activation in a child with a focal lesion using fMRI. Other research has used positron emission tomography to examine functional activation in children with brain damage (Muller et al, 1996; Shamoto and Chugani, 1996).

Three main conclusions emerged from our investigation. First, the pattern of activation observed for our 9 to 12-year-old healthy children was generally similar to that obtained for adults with similar experimental paradigms (Alivisatos and Petrides, 1997; Binder et al, 1997; Just et al, 1996, Kapur et al, 1994; Petersen et al, 1988; Warburton et al, 1996). Perhaps if we had used younger children the patterns would have been different. Second, each task showed extensive bilateral activation for the healthy children. This is inconsistent with notions of rigid lateralization (Kinsbourne and Hiscock, 1983; Van Kleeck, 1989). Third, a large unilateral lesion was associated with organization to homologous areas in the intact hemisphere. These results support a fairly widespread cognitive potential in the cortical substrate both within and between hemispheres (Engelien et al, 1995; Weiller et al, 1995).

Acknowledgments

This research was funded in part by a National Institute of Child Health and Human Development grant 5-F32-HD08255-02 and by a National Institute of Deafness and Communication Disorders grant 5-R01-HD23998, and by National Institute of Neurological Disorders and Stroke grant 1 PO1 NS35949-01 AI. We thank Claudine Martin for assistance in statistical analyses.

References

- ALIVISATOS, B. and PETRIDES, M. (1997). Functional activation of the human brain during mental rotation. *Neuropsychologia*, **35**, 111-118.
- ARAM, D.M. and EISELE, J.A. (1994). Intellectual stability in children with unilateral brain lesions. *Neuropsychologia*, **32**, 85-95.
- BATES, E., THAL, D., TRAUNER, D., FENSON, J., ARAM, D., EISELE, J. and NASS, R. (1997). From first words to grammar in children with focal brain injury. *Development. Neuropsychol.*, **13**, 275.
- BINDER, J.R., FROST, J.A., HAMMEKE, T.A., COX, R.W., RAO, S.M. and PRIETO, T. (1997). Human brain language areas identified in functional magnetic resonance imaging. *J. Neurosci.*, **17**, 353-362.
- BOOTH, J.R. and MACWHINNEY, B. (under review). Children's visual and auditory processing of complex sentences.
- BOOTH, J.R., MACWHINNEY, B., THULBORN, K.R., SACCO, K., VOYVODIC, J. and FELDMAN, H.M. (under review). Functional activation patterns in adults, children, and pediatric patients with brain lesions: Whole brain fMRI imaging during three different cognitive tasks
- BRAVER, T.S., COHEN, J.S., NYSTROM, L.E., JONIDES, J., SMITH, E.E. and NOLL, D. (1997). A parametric study of prefrontal cortex involvement in human working memory. *Neuroimage*, **5**, 49-62.
- COX, R. W. (1996) *Medical College of Wisconsin Analysis of Functional NeuroImages*.
- DANEMAN, M. and MERIKLE, P.M. (1996). Working memory and language comprehension: A meta-analysis. *Psychonomic Bull. Rev.*, **3**, 422-433.
- DUNN, L. and DUNN, L. (1981). *Peabody Picture Vocabulary Test Revised*. American Guidance Service, Circle Pines, MN.
- EDDY, W.F., FITZGERALD, M., GENOVESE, C.R., MOCKUS, A., and NOLL, D.C. (1997). Functional Imaging Analysis Software - Computational Olio. In: *Proceedings in Computational Statistics*, A. Pratt (Ed.), Physica-Verlag, Heidelberg.
- ENGELIEN, A., SILBERSWEIG, D., STERN, E., HUBER, W., DORING, W., FRITH, C. and FRACKOWIAK, R.S.J. (1995). The functional anatomy of recovery from auditory agnosia. *Bruin*, **118**, 1395-1409.
- HEFFNER, H.E. and HEFFNER, R.S. (1984). Temporal lobe lesions and perception of species-specific vocalizations in macaques. *Science*, **226**, 75-76.
- JUST, M. A., CARPENTER, P. A., KELLER, T. A., EDDY, W. F. and THULBORN, K. R. (1996). Brain activation modulated by sentence comprehension. *Science*, **274**, 114-116
- KAAS, J. H. (1995). The reorganization of sensory and motor maps in adult mammals. In: *The Cognitive Neurosciences*, M. Gazzaniga (Ed.), MIT Press, Cambridge, MA.
- KAPUR, S., ROSE, R., LIDDLE, P.F., ZIPURSKY, R.B. and BROWN, G.M. (1994). The role of the left prefrontal cortex in verbal processing: Semantic processing or willed action. *NeuroReport*, **5**, 2193-2196.
- KINSBOURNE, M. and HISCOCK, M. (1983). The normal and deviant development of functional lateralization in the brain. In: *Handbook of Child Psychology*, P. Mussen, M. Haith and J. Campos (Eds.), John Wiley, New York.
- KOSSLYN, S.M. (1994). *Image and bruin*. MIT Press, Cambridge, MA.
- KOSSLYN, S.M. and KOENIG, O. (1992) *Wet Mind: The New Cognitive Neuroscience*. Free Press, New York.
- LASHLEY, K.S. (1933). Interactive functions in the cerebral cortex. *Psycholog. Rev.*, **13**, 1-42.
- LEITER, R.G. (1980). *Leiter International Performance Scale*. Stoelting Co., WoodDale, IL.
- LENNEBERG, E.H. (1967). *Biological Foundations of Language*. John Wiley, New York.
- MILNER, B. (1973). Functional recovery after lesions of the nervous system: Sparing of language functions after early unilateral brain damage. *Neurosci. Res. Progr. Bull.* **12**, 2 13-217.

- MULLER, R.A., CHUGANI, H.T., MUZIK, O.M. and MANGER, T.J. (1996). Brain organization of motor and language functions following hemispherectomy: A [¹⁵O]-Water Positron emission tomography study. *J. Child Neurol.*, **13**, 16-22.
- MUTER, V., TAYLOR, S. and VARGHA-KHADEM, F. (1997). A longitudinal study of early intellectual development in hemiplegic children. *Neuropsychologia*, **35**, 289-299.
- PAPANICOLAOU, A.C., DISCENNA, A., GILLESPIE, L. and ARAM, D. (1990). Probe-evoked potential findings following unilateral left-hemisphere lesions in children. *Arch. Neurol.*, **47**, 562-566.
- PETERSEN, S. E., FOX, P. T., POSNER, M. I., MINTUN, M. and RAICHLE, M. E. (1988). Positron emission tomographic studies of the cortical anatomy of single word processing. *Nature*, **331**, 585-589.
- RAMACHANDRAN, V.S. (1993). Behavioral and magnetoencephalographic correlates of plasticity in the adult human brain. *Proc. Nation. Acad. Sci.*, **90**, 10413-10420.
- ROSENBERG, D.R., SWEENEY, J.A., GILLEN, J.S., CHANG, S.Y., VARANELLI, M.J., O'HEARN, K., ERB, P.A., DAVIS, D. and THULBORN, K.R. (1997). Magnetic Resonance Imaging of Children without Sedation: Preparation with Simulation. *J. Amer. Acad. Child Adol. Psychiat.*, **36**, 853-859.
- SEMEL, E., WIIG, E. and SECORD, W. (1989). *The Clinical Evaluation of Language Function - Revised*. The Psychological Corporation, San Antonio, TX.
- SHAMOTO, H. and CHUGANI, H.T. (1996). Glucose metabolism in the human cerebellum: An analysis of crossed cerebellar diaschisis in children with unilateral cerebral injury. *J. Child Neurol.*, **12**, 407-414.
- SHEPARD, R.N. and METZLER, J.N. (1971). Mental rotation of three-dimensional objects. *Science*, **171**, 701-703.
- SNODGRASS, J.G. and VANDERWART, M. (1980). A standardized set of 260 pictures: Norms of name agreement, image agreement, and visual complexity. *J. Exper. Psychol. : Hum. Learn. Mem.*, **6**, 174-214.
- STILES, J., TRAUNER, D., ENGEL, M. and NASS, R. (1997). The development of drawing in children with congenital focal brain injury: Evidence for the limited functional recovery. *Neuropsychologia*, **35**, 299-312.
- SUNDSTEN, J.W. (1994). *Digital anatomist: Interactive brain atlas*. Health Sciences Center for Educational Resources, University of Washington, Seattle, WA.
- TALAIRACH, J., and TOURNOUX, P. (1988). *Co-Planar Stereotaxic Atlas of the Human Brain*. Georg Thieme Verlag Stuttgart, New York.
- TEUBER, H.L. and RUEDEL, R.G. (1962). Behavior after cerebral lesions in children and adults. *Develop. Med. Child Neurol.*, **4**, 3-20.
- THULBORN K.R., DAVIS D., ERB P., STROJWAS M. and SWEENEY J.A. (1996). Clinical fMRI: Implementation and Experience. *NeuroImage*, **4**, S 101 -S 107.
- UNGERLEIDER, L.G. and HAXBY, J. V. (1994). 'What' and 'where' in the human brain. *Curr. Opin. Neurobiol.*, **4**, 157-165.
- VAN KLEEK, M.H. (1989). Hemispheric differences in global versus local processing of hierarchical visual stimuli by normal subjects: New data and meta-analysis. *Neuropsychologia*, **27**, 1165-1178.
- WARBURTON, E., WISE, R.J.S., PRICE, C.J., WEILLER, C., HADAR, U., RAMSAY, S. and FRACKOWIAK, R.S.J. (1996). Noun and verb retrieval by normal subjects: Studies with PET. *Brain*, **119**, 159-179.
- WEBSTER, M.J., BACHEVALIER, J., and UNGERLEIDER, L.G. (1995). Development and plasticity of visual memory circuits. In: *Maturational windows and adult cortical plasticity*, B. Julesz and I. Kovacs (Eds.), Addison-Wesley, New York.
- WEILLER, C., ISENEE, C., RIJNTJES, M., HUBER, W., MULLER, S., BIER, D., DUTSCHKA, K. WOODS, R.P., and DIENER H.C. (1995). Recovery from Wernicke's aphasia: a positron emission tomographic study. *Ann. Neurol.*, **37**, 723-732.

WOODCOCK, R.W. (1987). *Woodcock Reading Mastery Tests - Revised*. American Guidance Service, Circle Pines, MN.

Inquiries and reprint requests should be addressed to:

James R. Booth
Department of Communication Sciences and Disorders
Northwestern University
Frances Searle Building
2299 North Campus Drive
Evanston, Illinois, 60208-3560
Tel No 847-491-2519
Fax No 847-491-2494
E-mail j-booth@nwu.edu